

Are your MRI contrast agents cost-effective?

Learn more about generic Gadolinium-Based Contrast Agents.



**FRESENIUS
KABI**

caring for life

AJNR

**Abnormal White Matter Signal on MR
Imaging Is Related to Abnormal Tissue
Microstructure**

J.L.Y. Cheong, D.K. Thompson, H.X. Wang, R.W. Hunt,
P.J. Anderson, T.E. Inder and L.W. Doyle

This information is current as
of December 21, 2024.

AJNR Am J Neuroradiol 2009, 30 (3) 623-628

doi: <https://doi.org/10.3174/ajnr.A1399>

<http://www.ajnr.org/content/30/3/623>

ORIGINAL
RESEARCH

J.L.Y. Cheong
D.K. Thompson
H.X. Wang
R.W. Hunt
P.J. Anderson
T.E. Inder
L.W. Doyle



Abnormal White Matter Signal on MR Imaging Is Related to Abnormal Tissue Microstructure

BACKGROUND AND PURPOSE: White matter signal-intensity abnormalities (WMSA) on MR imaging are related to adverse neurodevelopmental outcome in extremely preterm infants. Diffusion tensor imaging (DTI) may detect alterations in cerebral white matter microstructure and thus may help confirm the pathologic basis of WMSA. This study aimed to relate regional DTI measures with severity of WMSA in very preterm infants.

MATERIALS AND METHODS: One hundred eleven preterm infants (birth weight, <1250 g and/or gestational age, <30 weeks) were scanned at term-equivalent age (1.5T). WMSA were classified as normal, focal, or extensive. Apparent diffusion coefficient (ADC), fractional anisotropy (FA), axial (λ_1), and radial ($(\lambda_2 + \lambda_3)/2$) diffusivity were calculated in 12 regions of interest placed in the bilateral posterior limbs of the internal capsule, frontal (superior and inferior), sensorimotor, and occipital (superior and inferior) white matter regions. Data were compared by using 1-way analysis of variance, with a Bonferroni correction for multiple comparisons.

RESULTS: Thirty-nine infants had normal, 59 infants had focal, and 13 infants had extensive WMSA. Compared with infants with normal or focal WMSA, infants with extensive WMSA had significantly lower FA in the internal capsule ($P < .001$), right inferior frontal regions ($P < .05$), and right superior occipital regions ($P = .01$); and higher radial diffusivity in the right internal capsule ($P = .005$), bilateral sensorimotor ($P < .05$), and right superior occipital regions ($P < .05$). Compared with infants with normal WMSA, infants with extensive WMSA had significantly higher ADC in bilateral sensorimotor regions ($P < .01$) and right superior occipital regions ($P = .01$), and lower axial diffusivity in the bilateral sensorimotor regions ($P < .05$).

CONCLUSIONS: There are significant region-specific changes in ADC, FA, radial diffusivity, and axial diffusivity in preterm infants with extensive WMSA. Altered radial diffusivity was most prominent. This implies that disrupted premyelinating oligodendroglia is the major correlate with extensive WMSA rather than axonal pathology.

Extremely preterm infants are at high risk of brain injury and subsequent cognitive and motor disability.^{1,2} The main cerebral pathologies in the preterm neonate are germinal matrix-intraventricular hemorrhage, posthemorrhagic hydrocephalus, and periventricular leukomalacia (PVL). Cystic PVL is readily identified by cranial ultrasonography and is well recognized as being an important predictor of motor disability. However, with the availability of MR imaging, it is now increasingly evident that noncystic PVL is the most common white matter abnormality in the preterm infant brain.^{3,4} The 2 main appearances on MR imaging of noncystic white matter injury in ex-preterm infants have been described as “diffuse excessive high signal intensity” (DEHSI) on T2-weighted images and focal or multifocal shortening of T1 and T2 relax-

ation times in the white matter.⁴⁻⁶ These classifications are based on qualitative assessments and have been criticized because these “abnormalities” may represent normal developmental change or imaging artifacts.⁷ However, these white matter signal-intensity abnormalities (WMSA) have been demonstrated to be important predictors of subsequent motor dysfunction and poor developmental outcome.^{6,8,9}

Diffusion tensor MR imaging (DTI) assesses random motion of water molecules within biologic tissue and can provide insight into white matter microstructure and development. With DTI, several measures of water diffusivity, including apparent diffusion coefficient (ADC), fractional anisotropy (FA), and radial and axial diffusivity, can be obtained. ADC is a measure of water diffusion within tissue and is influenced by random thermal motion and the presence of cell membranes, macromolecules, and white matter fibers.¹⁰ Water displacement within tissue can be represented by 3D diffusion ellipsoids, which reflect 3 major eigenvectors, λ_1 , λ_1 , and λ_3 . The degree to which the diffusion ellipsoid deviates from being spheric is quantitated by FA values, which are zero for isotropic diffusion and increased for higher degrees of anisotropy. Mathematically, the FA is the SD of the eigenvalues of the diffusion tensor divided by the ADC and is given as a percentage. The primary eigenvector (λ_1) corresponding to the maximum diffusivity is oriented parallel to white matter fibers. Its eigenvalue is referred to as “axial diffusivity,” where higher values reflect better axonal integrity. The secondary (λ_2) and tertiary (λ_3) eigenvectors are assumed to be in the transverse plane oriented perpendicular to the fiber direction. The aver-

Received August 19, 2008; accepted after revision October 5.

From the Victorian Infant Brain Studies (J.L.Y.C., R.W.H., P.J.A., T.E.I., L.W.D.), Murdoch Children’s Research Institute, Parkville, Australia; Royal Women’s Hospital Melbourne (J.L.Y.C., R.W.H., T.E.I., L.W.D.), Parkville, Australia; Department of Obstetrics and Gynecology (J.L.Y.C., L.W.D.), University of Melbourne, Howard Florey Institute (D.K.T., H.X.W.), Parkville, Australia; Royal Children’s Hospital (R.W.H., T.E.I.), Melbourne, Australia; Department of Psychology (P.J.A.), University of Melbourne, Melbourne, Australia; and St. Louis Children’s Hospital (T.E.I.), Washington University, St. Louis, Mo.

This work was supported by grants from the National Health and Medical Research Council of Australia (project grant number 237117), Murdoch Children’s Research Institute, The Royal Women’s Hospital Research Foundation, and the Jack Brockhoff Foundation.

Please address correspondence to J.L.Y. Cheong, Level 7, Newborn Research, Royal Women’s Hospital, 20 Flemington Rd, Parkville, Vic 3052, Australia; e-mail: jeanie.cheong@thewomens.org.au



Indicates open access to non-subscribers at www.ajnr.org

DOI 10.3174/ajnr.A1399

age of their eigenvalues is referred to as “radial diffusivity,” and higher values indicate that more water diffusion is occurring perpendicular to axons, representing less myelination or reduced oligodendroglial integrity.

The value of diffusion MR imaging in the preterm infant has been under much investigation. Diffusion abnormalities have been shown to be present before qualitative abnormalities in the white matter, including signal-intensity changes and cystic formation in the unmyelinated neonate brain.¹¹⁻¹³ Indeed in preterm infants with white matter abnormalities on MR imaging, diffusion parameters are altered as well.¹⁴⁻¹⁶ The classification of the white matter abnormalities in those studies differed, ranging from DEHSI to overt white matter lesions on MR imaging. In addition, these studies were based on a relatively small numbers of infants. Thus, there is a need to further establish in a larger cohort that WMSA on T1- and T2-weighted MR imaging in preterm infants are a reflection of underlying pathology rather than imaging artifacts alone.

The aim of this study was to compare the diffusion parameters (ie, ADC, FA, axial diffusivity, and radial diffusivity) from several preassigned cerebral white matter regions with the severity of WMSA graded on conventional T1- and T2-weighted MR imaging in a large cohort of extremely preterm infants.

Materials and Methods

Patients

This study is part of a large cohort study assessing preterm brain development by using MR imaging. Two hundred twenty-seven preterm infants (birth weight, <1250 g or gestational age, <30 weeks) were recruited during a 3-year period at the Royal Women’s Hospital in Melbourne. Permission was granted by the Royal Women’s Hospital Research and Ethics Committees, and written informed parental consent was necessary for participation in this study.

MR Imaging

MR imaging examination was performed between 38 and 42 weeks’ corrected gestational age by using a 1.5T Signa LX EchoSpeed system (GE Healthcare, Milwaukee, Wis). We performed the following sequences: 1) a 3D Fourier transform spoiled gradient recalled-echo sequence (1.5-mm coronal sections; flip angle, 45°; TR, 35 ms; TE, 5 ms; FOV, 18 cm; matrix, 256 × 256); 2) a double-echo (proton-attenuation and T2-weighted) spin-echo sequence (3-mm axial sections; TR, 3000 ms; TE, 36 and 162 ms; FOV, 18 cm; matrix, 256 × 256, interleaved acquisition); and 3) a line scan sequence (4- to 6-mm axial sections with a 0.5- to 1-mm gap; TR, 2139 ms; TE, 78 ms; FOV, 22 cm; matrix, 128 × 128; 2 images at $b=5$ s/mm²; 6 images at $b=700$ s/mm². The diffusion gradients for $b=700$ s/mm² were oriented in 6 noncollinear directions). Before the MR imaging examination, infants were fed, swaddled, and placed in a Vac Fix beanbag (S&S Par Scientific, Odense, Denmark) designed to keep the infant still and supported in the MR imaging scanner.

MR images were qualitatively classified by using a standardized system^{3,5} by 2 independent raters who were blinded to the clinical history and cranial sonographic findings. The MR imaging diagnosis of WMSA required either T1 hyperintensity in the absence of marked T2 hypointensity (which was interpreted as astrogliosis) or T1 hyperintensity with substantial T2 hypointensity (which was interpreted as foci of hemorrhage) or significant T2 hyperintensity (excessive hyperintensity). The classification into “focal” and “extensive” was a reflec-

tion of how widespread these WMSA were present in the neonate brain. MR images were classified as having a “focal” WMSA if 1 lobar region was involved, and “extensive” WMSA if >1 lobar region was involved or cystic change indicative of areas of tissue dissolution was present.

DTI Analysis

For each voxel, 3 eigenvalues and eigenvectors of the diffusion tensor and the ADC were calculated. Apparent diffusion was measured according to the Stejskal and Tanner equation,¹⁷ with the diffusion tensor elements estimated for each voxel by nonlinear regression, as suggested by Basser and Pierpaoli.¹⁸

DTI analysis was performed off-line by using XPhase image analysis software (SE Maier, Boston, Mass). ADC, FA, axial (λ_1), and radial $(\lambda_2 + \lambda_3)/2$ diffusivity were calculated in 12 manually selected regions of interest in the brain, located on 2 axial sections. The region-of-interest placement was performed by 1 individual and then checked by another who was experienced in neonatal neuroimaging. The superior axial section was taken at a level just above the lateral ventricles, and regions of interest were located in bilateral frontal, sensorimotor, and occipital white matter regions (Fig 1A). The inferior section was taken at a level through the basal ganglia and posterior limb of the internal capsule (PLIC), and regions of interest were located in the bilateral middle third of the PLICs and the frontal and occipital white matter regions (Fig 1B). The diffusion-weighted, ADC, relative anisotropy, and FA images were viewed simultaneously in the axial plane for region-of-interest placement.

Statistical Analysis

Diffusion measures from the 3 groups of varying severity of white matter abnormalities on MR imaging were compared by using 1-way analysis of variance, with a Bonferroni correction for multiple comparisons. A *P* value < .05 (following Bonferroni correction) was considered significant.

Results

Of the 227 preterm infants who were recruited, 111 had MR imaging examinations at term-corrected age in which all 3 sequences (ie, conventional T1-, T2-weighted, and diffusion-weighted line scan) were obtained and the data were analyzable. The clinical characteristics of the infants are summarized in Table 1. There were no significant differences in any of the clinical characteristics between the subgroup analyzed for this study and the whole preterm cohort (data not shown).

ADC in Relation to WMSA

Compared with infants with normal WMSA, infants with extensive WMSA had significantly higher ADC in the right superior occipital and bilateral sensorimotor regions (Table 2).

FA in Relation to WMSA

Infants with extensive WMSA had significantly lower FA in bilateral internal capsules and right frontal and right occipital regions compared with infants with normal and focal WMSA on MR imaging (Table 3).

Axial Diffusivity in Relation to WMSA

Compared with infants with normal WMSA, infants with extensive WMSA had significantly lower axial diffusivity in the right internal capsule and significantly higher axial diffusivity in bilateral sensorimotor regions (Table 4).

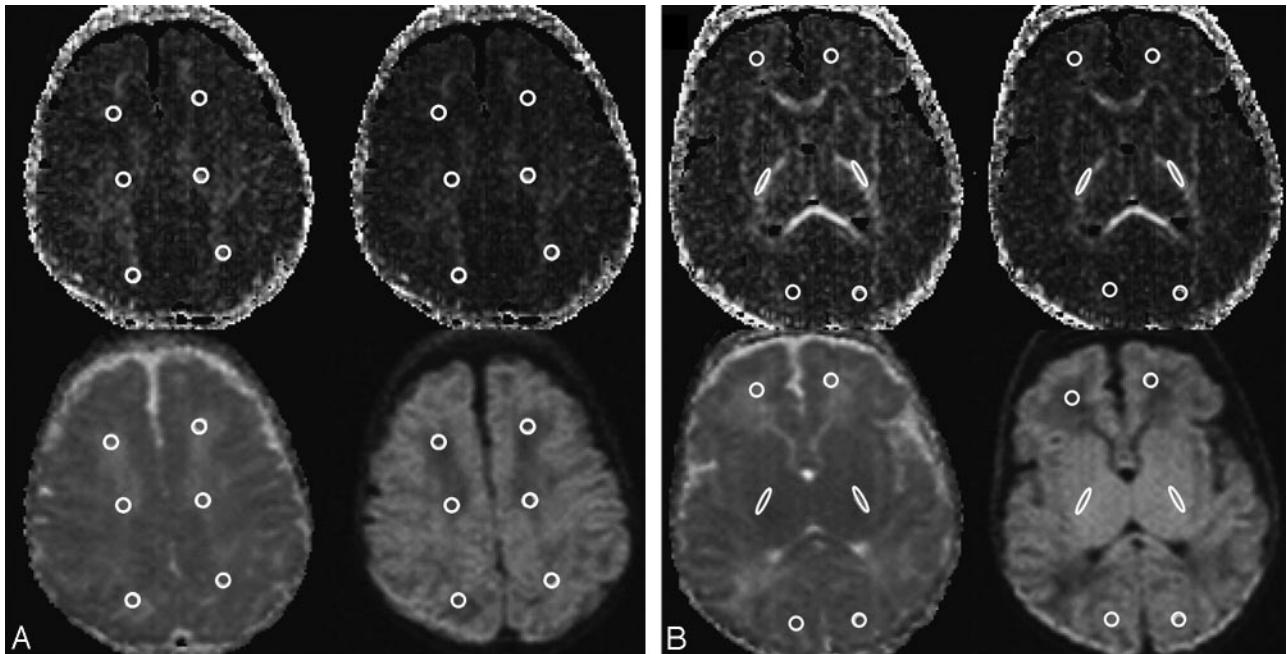


Fig 1. A, Axial line scan images obtained at the level just above the superior margins of the lateral ventricles. The 4 images used to determine the regions of interest were the following: 1) FA (top left), 2) relative anisotropy (top right), 3) ADC (bottom left), and 4) diffusion-weighted (bottom right). Six regions of interest were located in the following regions: frontal white matter, sensorimotor white matter, and occipital white matter. B, Axial line scan image obtained at the level of the basal ganglia and PLIC. The 4 images used to determine the regions of interest were the following: 1) FA (top left), 2) relative anisotropy (top right), 3) ADC (bottom left), and 4) diffusion-weighted (bottom right). Six regions of interest were located in the following regions: frontal white matter, middle third of the PLICs, and occipital white matter.

Table 1: Clinical characteristics of infants

Characteristics	Preterm Cohort (n = 111)
Birth weight (g) (mean, SD)	992 (224)
Gestational age at birth (weeks) (mean, SD)	27.4 (1.8)
No. of males (%)	59 (53.1)
No. of singletons (%)	64 (57.7)
No. small for gestational age (%)*	8 (7.2)
Gestational age at MRI (weeks) (mean, SD)	40.2 (1.3)
No. of intraventricular hemorrhages (%)	
Grade I	2 (1.8)
Grade II	7 (6.3)
Grade III or IV	6(5.4)
No. of cases of cystic periventricular leukomalacia (%)	5 (4.5)

Note:—MRI indicates MR imaging.
* Birth weight ≤ 2 SDs for age and sex.

Radial Diffusivity in Relation to WMSA

Compared with infants with normal WMSA, infants with extensive WMSA had significantly higher radial diffusivity in the right inferior frontal, right internal capsule, and right superior occipital and bilateral sensorimotor regions (Table 5). In addition, compared with infants with focal WMSA, infants with extensive WMSA had significantly higher radial diffusivity in the regions listed above, with the exception of the right superior frontal region.

In all occasions, there was a trend for stepwise reductions in the anisotropy and increases in the ADC across the grading of severity of brain injury.

Discussion

This study has demonstrated important associations between a global WMSA score on MR imaging and diffusion parameters. Increased radial diffusivity and decreased FA in the inter-

nal capsules and sensorimotor regions of infants with extensive WMSA on MR imaging were the most prominent findings. In addition, ADC was increased in the right superior occipital and bilateral sensorimotor regions, and axial diffusivity was decreased in the right internal capsule and bilateral sensorimotor regions. These findings suggest that extensive WMSA on conventional T1- and T2-weighted MR imaging are associated with important microstructural abnormalities, in particular, radial diffusivity. This implies that the major correlate of extensive WMSA on MR imaging may be the disruption within the premyelinating oligodendroglia rather than axonal pathology. In addition, the results also suggest that there are vulnerable brain regions that display more microstructural derangement on diffusion imaging, including the sensorimotor region and internal capsules.

Altered diffusion parameters have been documented in preterm infants with abnormal white matter on MR imaging and in those with abnormal neurologic outcome. Previous studies have found that mean ADC increased in preterm infants with white matter abnormalities on MR imaging, including diffuse excessive high-signal intensities on MR imaging, and in infants with overt white matter lesions (eg, diffuse or nodular white matter hypo- or hyperintensities and cystic lesions).^{14,15} Relative anisotropy was lower in infants with white matter lesions, and it was speculated that this may have been due to a decrease in directionality as a result of fiber tracts that were disrupted. Subsequent to these studies, radial diffusivity and axial diffusivity were also found to be deranged in infants with diffuse excessive WMSA on MR imaging.¹⁶ The authors concluded that the findings may have reflected delayed myelination in infants with white matter abnormalities on MR imaging.

The findings from this study are in keeping with previously

Table 2: Relationship between ADC (10⁻³ mm²/s) and WMSA*

Brain Region	WMSA on MRI			P Values			
	Normal (n = 39)	Focal (n = 59)	Extensive (n = 13)	Overall	Normal vs Focal†	Normal vs Extensive†	Focal vs Extensive†
Inferior frontal							
Right	1.74 (0.16)	1.75 (0.16)	1.85 (0.23)	.09	.99	.10	.15
Left	1.69 (0.14)	1.70 (0.15)	1.79 (0.19)	.09	.99	.09	.16
Inferior occipital							
Right	1.64 (0.14)	1.68 (0.12)	1.69 (0.11)	.17	.26	.47	.99
Left	1.65 (0.16)	1.66 (0.17)	1.71 (0.16)	.44	.99	.60	.99
Internal capsule							
Right	1.09 (0.04)	1.09 (0.04)	1.11 (0.06)	.24	.99	.52	.27
Left	1.12 (0.11)	1.13 (0.14)	1.12 (0.05)	.94	.99	.99	.99
Superior frontal							
Right	1.64 (0.15)	1.71 (0.14)	1.73 (0.16)	.06	.07	.22	.99
Left	1.59 (0.15)	1.66 (0.15)	1.71 (0.19)	.06	.09	.06	.92
Sensorimotor							
Right	1.41 (0.20)	1.51 (0.21)	1.65 (0.26)	.002‡	.07	.002‡	.10
Left	1.44 (0.18)	1.50 (0.21)	1.63 (0.18)	.009‡	.30	.007‡	.10
Superior occipital							
Right	1.66 (0.18)	1.81 (0.15)	1.65 (0.14)	.004‡	.99	.01‡	.003‡
Left	1.64 (0.17)	1.72 (0.18)	1.65 (0.18)	.39	.99	.53	.68

Note:—ADC indicates apparent diffusion coefficient; WMSA, white matter signal-intensity abnormalities.

* Values are mean (SD).

† P values after Bonferroni correction.

‡ Significant P values.

Table 3: Relationship between FA (%) and WMSA*

Brain Region	WMSA on MRI			P Values			
	Normal (n = 39)	Focal (n = 59)	Extensive (n = 13)	Overall	Normal vs Focal†	Normal vs Extensive†	Focal vs Extensive†
Inferior frontal							
Right	15.1 (4.62)	13.35 (4.87)	9.14 (6.80)	.002‡	.29	.001‡	.02‡
Left	16.71 (4.53)	14.10 (4.96)	13.82 (6.73)	.15	.33	.10	.99
Inferior occipital							
Right	18.15 (4.78)	16.35 (4.32)	15.56 (4.53)	.09	.17	.23	.99
Left	18.53 (5.41)	17.34 (5.65)	15.42 (2.78)	.18	.84	.21	.73
Internal capsule							
Right	51.01 (4.39)	50.46 (4.08)	43.95 (7.62)	<.001‡	.99	<.001‡	<.001‡
Left	48.85 (5.62)	48.36 (4.32)	43.51 (7.69)	.006‡	.99	.006‡	.01‡
Superior frontal							
Right	14.24 (3.89)	12.71 (3.34)	13.02 (5.43)	.15	.16	.96	.99
Left	15.82 (4.34)	13.93 (4.19)	13.68 (4.78)	.08	.11	.37	.99
Sensorimotor							
Right	21.50 (7.78)	19.74 (7.50)	16.65 (5.00)	.12	.75	.13	.52
Left	20.82 (7.22)	19.64 (6.52)	18.10 (4.07)	.40	.99	.60	.99
Superior occipital							
Right	16.69 (5.45)	16.51 (3.99)	12.22 (5.60)	.01‡	.99	.01‡	.01‡
Left	16.16 (4.31)	15.92 (4.04)	13.73 (5.31)	.20	.99	.24	.30

Note:—FA indicates fractional anisotropy.

* Values are mean (SD).

† P values after Bonferroni correction.

‡ Significant P values.

published studies. We found abnormal diffusion parameters, in particular radial diffusivity in infants with extensive WMSA on MR imaging. Radial diffusivity describes water ADC perpendicular to axons. Data from studies on mature animals have shown that primary injury to myelin is associated with an increase in radial diffusivity, whereas primary injury to axons, such as wallerian degeneration, is associated with a decrease in axial diffusivity.^{19,20} However, our studies are at a stage of brain development in which there is little myelination but an abundance of premyelinating oligodendrocytes in the human cerebral white matter. During this maturational phase, the early differentiating oligodendrocytes are beginning to en-

sheath cerebral white matter axons, in preparation for myelination, which happens after term in the human.²¹⁻²³ These changes in the oligodendroglia, which subsequently result in changes in axonal size, axonal membranes, and intracellular axonal constituents, are likely to contribute to the normal decreases in the extracellular space and water content in cerebral white matter and thus to the normal decline in ADC and increases in FA and radial anisotropy.²⁴⁻²⁶ Thus, 1 hypothesis to explain the changes demonstrated in this study and previous studies for the failure of the reduction in ADC from higher levels in the premature infant to the lower levels of the term infant in the presence of WMSA on MR imaging may relate to

Table 4: Relationship between axial diffusivity ($\times 10^{-3}$ mm²/s) and WMSA*

Brain Region	WMSA on MRI			P Values			
	Normal (n = 39)	Focal (n = 59)	Extensive (n = 13)	Overall	Normal vs Focal†	Normal vs Extensive†	Focal vs Extensive†
Inferior frontal							
Right	2.02 (0.16)	2.00 (0.16)	2.09 (0.22)	.29	.99	.76	.35
Left	1.96 (0.18)	1.93 (0.19)	2.03 (0.14)	.21	.99	.63	.23
Inferior occipital							
Right	1.93 (0.16)	1.96 (0.13)	1.96 (0.15)	.68	.99	.99	.99
Left	1.93 (0.17)	1.90 (0.21)	1.99 (0.17)	.26	.99	.96	.34
Internal capsule							
Right	1.79 (0.07)	1.77 (0.09)	1.71 (0.09)	.01‡	.69	.01‡	.06
Left	1.75 (0.18)	1.75 (0.15)	1.71 (0.09)	.64	.99	.99	.99
Superior frontal							
Right	1.87 (.16)	1.92 (0.17))	1.92 (0.23)	.42	.60	.99	.99
Left	1.85 (.16)	1.88 (0.19)	1.90 (0.21)	.58	.99	.99	.99
Sensorimotor							
Right	1.74 (0.17)	1.85 (0.28)	2.00 (0.34)	.004‡	.10	.004‡	.15
Left	1.78 (0.19)	1.83 (0.23)	1.97 (0.27)	.02‡	.59	.02‡	.13
Superior occipital							
Right	1.96 (.18)	1.91 (0.17)	2.02 (0.25)	.11	.67	.77	.14
Left	1.92 (0.17)	1.90 (0.18)	1.95 (0.23)	.64	.99	.99	.99

* Values are mean (SD).
† P values after Bonferroni correction.
‡ Significant P values.

Table 5: Relationship between radial diffusivity ($\times 10^{-3}$ mm²/s) and WMSA*

Brain Region	WMSA on MRI			P Values			
	Normal (n = 39)	Focal (n = 59)	Extensive (n = 13)	Overall	Normal vs Focal†	Normal vs Extensive†	Focal vs Extensive†
Inferior frontal							
Right	1.60 (0.17)	1.62 (0.17)	1.74 (0.24)	0.05‡	.99	.04‡	.11
Left	1.55 (0.16)	1.58 (0.15)	1.65 (0.21)	.15	.91	.17	.56
Inferior occipital							
Right	1.49 (0.15)	1.55 (0.14)	1.56 (0.12)	.10	.15	.34	.99
Left	1.48 (0.16)	1.50 (0.20)	1.55 (0.17)	.45	.99	.65	.99
Internal capsule							
Right	0.75 (0.06)	0.75 (0.06)	0.82 (0.10)	.004‡	.99	.005‡	.005‡
Left	0.79 (0.10)	0.79 (0.11)	0.83 (0.11)	.41	.99	.65	.61
Superior frontal							
Right	1.53 (0.14)	1.59 (0.15)	1.58 (0.21)	.19	.21	.99	.99
Left	1.47 (0.15)	1.52 (0.16)	1.56 (0.21)	.16	.42	.27	.99
Sensorimotor							
Right	1.28 (0.24)	1.37 (0.22)	1.56 (0.29)	.001‡	.16	.001‡	.03‡
Left	1.31 (0.19)	1.36 (0.22)	1.52 (0.24)	.008‡	.68	.006‡	.04‡
Superior occipital							
Right	1.52 (0.18)	1.49 (0.14)	1.65 (0.21)	.007‡	.99	.04‡	.005‡
Left	1.51 (0.16)	1.50 (0.17)	1.57 (0.18)	.40	.99	.84	.53

* Values are mean (SD).
† P values after Bonferroni correction.
‡ Significant P values.

prior injury to premyelinating oligodendrocytes and the subsequent failure of their development and ensheathment of axons.²⁷

In addition, there were inconsistent findings in relation to axial diffusivity, with a reduction in the internal capsule but an increase in the sensorimotor cortex regions. The internal capsule is a very tightly packed cabling network; thus, it is plausible that there may be a lack of sensitivity for the measures in these densely packed fiber tracts. The infants in this study were imaged at term-corrected age, many weeks after birth and presumed time of insult. Thus, chronic alterations in axial diffusivity consistent with axonal loss may be more visible in the

less densely packed fibers as they emerge and spread into the sensorimotor region.

There were no significant differences in any of the diffusion parameters in infants with normal and focal WMSA. This would suggest that less extensive WMSA changes on conventional T1- and T2-weighted MR imaging in ex-preterm infants were not associated with significant MR imaging-detectable microstructural disruption on these diffusion analyses during this period of brain development. There are, however, limitations in the diffusion data that were acquired in this study that may have led to a reduction in sensitivity to milder forms of microstructural disruption. The data were obtained at a low

field strength (1.5T) with a large section thickness (4–6 mm) and a very limited number of 6 directions. Newer diffusion imaging techniques with more directions and higher resolution in higher field magnets may have greater sensitivity for milder forms of white matter microstructural disturbance.

Another notable finding from this study relates to the fact that altered diffusivity was region-specific, involving particularly the sensorimotor pathways of the brain. Severe white matter abnormality on MR imaging is known to be most strongly associated with motor dysfunction.⁶ We found that many of the diffusion alterations involved the sensorimotor regions and the internal capsules, which are areas of increased white matter maturity in the neonate. This may partly explain the strong relationship between qualitative extensive white matter abnormalities in ex-preterm infants and poor neuro-motor outcome.

In comparison with previous studies, which have been on smaller cohorts (<50 infants), our findings have been based on a much larger cohort. The consistent finding that abnormal diffusion parameters are associated with WMSA further adds weight to existing evidence that WMSA on MR imaging are related to abnormal tissue microstructure and are not solely explained by image artifacts or windowing.

One of the drawbacks of the current study is that the diffusion information was obtained from prespecified regions of interest within the brain. It would be useful to obtain diffusion information from “diffusion maps” encompassing the whole brain to be able to further define the abnormal areas within the brain in ex-preterm infants with WMSA. With technical advancements in postacquisition diffusion analysis, it may be possible to derive diffusion maps from similar cohorts in the future.

Future directions in this research area would also include MR tractography to explore the associations between altered diffusivity and altered fiber tract development in these infants. The infants in this study are being longitudinally evaluated for neurodevelopmental outcomes; thus, evaluation of the relationships between diffusion measures, WMSA, and childhood outcomes will be possible.

Conclusions

Signal-intensity abnormalities in the white matter on MR imaging in ex-preterm infants at term-corrected age are associated with derangement in all diffusion parameters, with radial diffusivity being the most prominent. The severity of the derangement is related to the severity of the regional involvement of WMSA. These findings in vivo concur with in vitro and experimental studies that imply disruption of premyelinating oligodendroglia as the major correlate with extensive WMSA in the preterm neonate.

Acknowledgments

We thank Marilyn Bear for her assistance with recruitment, liaison with families, and care of babies in the MR imaging scanner and all the families for their willingness to participate in this study.

References

1. Marlow N, Wolke D, Bracewell MA, et al, for the EPICure Study Group. **Neurologic and developmental disability at six years of age after extremely preterm birth.** *N Engl J Med* 2005;352:9–19
2. Doyle LW, Anderson PJ. **Improved neurosensory outcome at 8 years of age of extremely low birthweight children born in Victoria over three distinct eras.** *Arch Dis Child Fetal Neonatal Ed* 2005;90:F484–88
3. Inder TE, Anderson NJ, Spencer C, et al. **White matter injury in the premature infant: a comparison between serial cranial sonographic and MR findings at term.** *AJNR Am J Neuroradiol* 2003;24:805–09
4. Maalouf E, Duggan P, Rutherford M, et al. **Magnetic resonance imaging of the brain in a cohort of extremely preterm infants.** *J Pediatr* 1999;135:351–57
5. Inder TE, Wells SJ, Mogridge NB, et al. **Defining the nature of the cerebral abnormalities in the premature infant: a qualitative magnetic resonance imaging study.** *J Pediatr* 2003;143:171–79
6. Woodward LJ, Anderson PJ, Austin NC, et al. **Neonatal MRI to predict neurodevelopmental outcomes in preterm infants.** *N Engl J Med* 2006;355:685–94
7. Volpe JJ. **Cerebral white matter injury of the premature infant: more common than you think.** *Pediatrics* 2003;112:176–80
8. Krishnan ML, Dyet LE, Boardman JP, et al. **Relationship between white matter apparent diffusion coefficients in preterm infants at term-equivalent age and developmental outcome at 2 years.** *Pediatrics* 2007;120:e604–09
9. Rose J, Mirmiran M, Butler EE, et al. **Neonatal microstructural development of the internal capsule on diffusion tensor imaging correlates with severity of gait and motor deficits.** *Dev Med Child Neurol* 2007;49:745–50
10. Christian B. **The basis of anisotropic water diffusion in the nervous system: a technical review.** *NMR Biomed* 2002;15:435–55
11. Inder T, Huppi PS, Zientara GP, et al. **Early detection of periventricular leukomalacia by diffusion-weighted magnetic resonance imaging techniques.** *J Pediatr* 1999;134:631–34
12. Fu J, Xue X, Chen L, et al. **Studies on the value of diffusion-weighted MR imaging in the early prediction of periventricular leukomalacia.** *J Neuroimaging* 2009;19:13–8
13. Bozzao A, Di Paolo A, Mazzoleni C, et al. **Diffusion-weighted MR imaging in the early diagnosis of periventricular leukomalacia.** *Eur Radiol* 2003;13:1571–76
14. Huppi PS, Murphy B, Maier SE, et al. **Microstructural brain development after perinatal cerebral white matter injury assessed by diffusion tensor magnetic resonance imaging.** *Pediatrics* 2001;107:455–60
15. Counsell SJ, Allsop JM, Harrison MC, et al. **Diffusion-weighted imaging of the brain in preterm infants with focal and diffuse white matter abnormality.** *Pediatrics* 2003;112:1–7
16. Counsell SJ, Shen Y, Boardman JP, et al. **Axial and radial diffusivity in preterm infants who have diffuse white matter changes on magnetic resonance imaging at term-equivalent age.** *Pediatrics* 2006;117:376–86
17. Stjeskal E, Tanner J. **Spin diffusion measurements: spin echoes in the presence of a time-dependent field gradient.** *J Chem Phys* 1965;42:288–92
18. Basser PJ, Pierpaoli C. **Microstructural and physiological features of tissues elucidated by quantitative-diffusion-tensor MRI.** *J Magn Reson B* 1996;111:209–19
19. Song S-K, Sun S-W, Ramsbottom MJ, et al. **Dysmyelination revealed through MRI as increased radial (but unchanged axial) diffusion of water.** *Neuroimage* 2002;17:1429–36
20. Song S-K, Yoshino J, Le TQ, et al. **Demyelination increases radial diffusivity in corpus callosum of mouse brain.** *Neuroimage* 2005;26:132–40
21. Kinney H, Brody B, Kloman A, et al. **Sequence of central nervous system myelination in human infancy. II. Patterns of myelination in autopsied infants.** *J Neuropathol Exp Neurol* 1988;47:217–34
22. Back S, Luo N, Borenstein N, et al. **Late oligodendrocyte progenitors coincide with the developmental window of vulnerability for human perinatal white matter injury.** *J Neurosci* 2001;21:1302–12
23. Back S, Luo N, Borenstein N, et al. **Arrested oligodendrocyte lineage progression during human cerebral white matter development: dissociation between the timing of progenitor differentiation and myelinogenesis.** *J Neuropathol Exp Neurol* 2002;61:197–211
24. Wimberger D, Roberts T, Barkovich A, et al. **Identification of “premyelination” by diffusion-weighted MRI.** *J Comput Assist Tomogr* 1995;19:28–33
25. Miller S, Vigneron D, Henry R, et al. **Serial quantitative diffusion tensor MRI of the premature brain: development in newborns with and without injury.** *J Magn Reson Imaging* 2002;16:621–32
26. Huppi PS, Maier SE, Peled S, et al. **Microstructural development of human newborn cerebral white matter assessed in vivo by diffusion tensor magnetic resonance imaging.** *Pediatr Res* 1998;44:584–90
27. Volpe JJ. *Neurology of the Newborn.* 5th ed. Philadelphia: Saunders; 2008:423