

The **next generation** GBCA  
from Guerbet is here

Explore new possibilities >

Guerbet | 

© Guerbet 2024 GUOB220151-A

# AJNR

## **Radiation-induced optic neuropathy: characteristic appearances on gadolinium-enhanced MR.**

P A Hudgins, N J Newman, W P Dillon and J C Hoffman, Jr

*AJNR Am J Neuroradiol* 1992, 13 (1) 235-238

<http://www.ajnr.org/content/13/1/235>

This information is current as  
of July 2, 2024.

# Radiation-Induced Optic Neuropathy: Characteristic Appearances on Gadolinium-Enhanced MR

Patricia A. Hudgins,<sup>1</sup> Nancy J. Newman,<sup>2</sup> William P. Dillon,<sup>3</sup> and James C. Hoffman, Jr.<sup>1</sup>

**Purpose:** To assess the value of contrast-enhanced MR in the evaluation of radiation-induced optic neuropathy. **Materials and Methods:** Three patients with rapid visual loss 1½ to 3 years after radiation therapy to the optic nerves were studied with gadopentetate dimeglumine-enhanced MR images. All patients received over 5000 cGy, experienced rapid, permanent visual loss over several days to weeks, and underwent MR within weeks of presentation. **Results:** Enhanced MR images on each patient revealed focal discrete enhancement of the intracranial optic nerve. One patient underwent biopsy of the enhancing segment; this revealed pathologic changes of radiation optic neuropathy. Optic nerve enhancement in a patient with visual loss and a prior history of radiation therapy to the orbits or optic nerves suggests radiation optic neuropathy. **Conclusion:** Contrast-enhanced MR of the orbits, optic nerves, and chiasm is the imaging test of choice in patients with vision loss after radiation therapy for sellar or skull base disease; MR findings may obviate the need for biopsy.

**Index terms:** Therapeutic radiology, complications; Nerves, optic (II), magnetic resonance; Orbits, magnetic resonance; Neuropathy; Contrast media, paramagnetic

AJNR 13:235–238, January/February 1992

Radiation therapy (RT), either alone or in combination with surgery or chemotherapy, is an important therapeutic modality for many lesions of the brain, skull base, and extracranial head and neck. Complications of high-dose radiation, although uncommon, may occur. The most devastating complication of RT, radionecrosis, may involve normal tissues and may mimic recurrent disease on both the clinical presentation and follow-up imaging studies. We report three cases of radiation-induced optic neuropathy detected with gadopentetate dimeglumine (Gd-DTPA)-enhanced magnetic resonance (MR) imaging. Biopsy of the involved optic nerve in one patient confirmed the diagnosis of radiation-induced optic neuropathy.

## Materials and Methods

Three patients presented with visual symptoms referable to the anterior visual pathways 1½ to 3 years after receiving RT that included the prechiasmatic optic nerves and the chiasm within the field. MR was performed within several weeks of onset of symptoms. MR (1.5 T; General Electric, Milwaukee, WI, or Philips, Shelton, CT) techniques included precontrast T1-weighted images 500–800/15–30/1–2 (TR/TE/excitations) in both the axial and coronal planes; two patients also had T2-weighted axial images (1800–2500/20–70 or 40–90/1). Gd-DTPA (Berlex; Wayne, NJ) was administered in a standard dose (0.1 mmol/kg) and immediate thin section (3–5 mm) T1-weighted images were obtained in either the axial or coronal plane through the optic nerves and chiasm. One patient underwent an additional axial postcontrast T1-weighted sequence using fat suppression (spectral presaturation inversion recovery).

## Case Reports

### Case 1

A 72-year-old woman presented with diplopia and a left partial third nerve palsy; prolactin level at presentation was 300 ng/mL and MR images revealed a large sellar mass with suprasellar extension and invasion of the left cavernous sinus. She underwent a transsphenoidal hypophysectomy and subtotal resection of a pituitary adenoma; invasion of the left cavernous sinus was confirmed at surgery.

Received March 11, 1991; accepted and revision requested May 3; revision received July 31.

<sup>1</sup> Department of Radiology, Section of Neuroradiology, Emory University School of Medicine, 1364 Clifton Road, N.E., Atlanta, GA 30322. Address reprint requests to P. A. Hudgins.

<sup>2</sup> Departments of Ophthalmology and Neurology, Emory University School of Medicine, Atlanta, GA 30322.

<sup>3</sup> Department of Radiology, University of California, San Francisco, CA.

AJNR 13:235–238, Jan/Feb 1992 0195-6108/92/1301-0235

© American Society of Neuroradiology

Postoperative RT to the pituitary fossa, which was begun 7 weeks after surgery, consisted of 5400 cGy using a three-field technique with 180 cGy per day for 30 treatments. Her third nerve palsy and diplopia resolved and she experienced no visual complaints. Thirty-five months later the patient developed headaches and visual loss, referable to the right optic nerve, occurring over a several day period. An MR with Gd-DTPA was performed which revealed no recurrent tumor. Unenhanced T1- and T2-weighted images through the orbits and optic nerves were normal. Contrast-enhanced T1-weighted images revealed a mildly enlarged right prechiasmic optic nerve with focal enhancement that extended for approximately 1 cm (Fig. 1). A presumptive diagnosis of radiation optic neuropathy was made. Her visual loss did not resolve.

#### Case 2

A 56-year-old woman underwent left maxillectomy for recurrent adenoid cystic carcinoma of the left parotid gland. She was treated with two cycles of postoperative chemotherapy with cisplatin and adriamycin. This was followed by local radiation therapy consisting of a specified tumor dose of 6600 cGy at 200 cGy per fraction. Review of the radiation fields suggested volume maximums of 7000–7500 cGy to the inferior left orbit and medial right orbit. Therefore, although the left optic nerve received a higher dose of radiation to a larger segment, several millimeters of the right posterior optic nerve did receive 6500–7000 cGy. Twenty-four months later she presented with painless, progressive visual loss in the right eye during a 2-week period. A postcontrast T1-weighted MR revealed focal enhancement of a mildly enlarged right prechiasmic optic nerve (Fig. 2). Precontrast T1-weighted images, T2-weighted images through the orbits and optic nerves, and a postcontrast fat-suppression sequence obtained in the axial plane through the orbits were normal. No recurrent facial, parotid, or skull base mass was seen. However, although the presumed diagnosis was radiation optic neuropathy, the patient was felt to be at high risk for recurrent disease, and an open biopsy was performed. Pathology showed macrophages, pronounced reactive gliosis, and

fibrosis and hyalinosis of small blood vessels, confirming the prebiopsy impression of radiation optic neuropathy.

#### Case 3

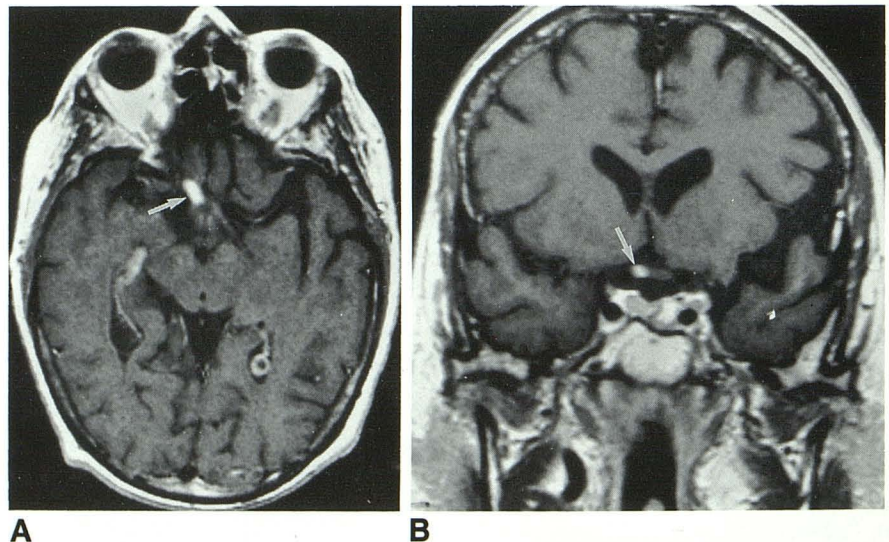
An elderly woman was diagnosed with an extensive nasopharyngeal carcinoma arising in the right fossa of Rosenmuller extending to the skull base. She was treated with fluorouracil and cisplatin, followed by radiation therapy. A tumor dose of 5040 cGy was delivered at 180 cGy per fraction, followed by an additional 1400 cGy at 200 cGy per day. Radiation fields included the nasopharynx, base of skull, posterior orbits, and intraorbital and intracranial optic nerves to the optic chiasm. Eighteen months later she presented with bilateral visual loss. Precontrast T1-weighted images were normal. Postcontrast MR images revealed enhancement of the intracranial prechiasmic right and left optic nerves over a short segment (Fig. 3). The presumed cause was radiation optic neuropathy, and she was treated with corticosteroids. Her visual loss was permanent.

#### Discussion

Visual loss in a patient who has undergone surgery, chemotherapy, or RT alone, or as adjuvant therapy for skull base or sella tumor, may be secondary to recurrent or progressive tumor, radiation-induced neoplasms, arachnoidal adhesions around the chiasm, or radiation retinopathy or optic neuropathy (1). The clinical presentation may suggest the etiology of the visual loss. Only radiation optic neuropathy causes a rapid deterioration for a period of days to weeks, while the remaining causes for visual compromise usually, though not invariably, progress for a period of weeks to months (1).

RT affects both normal and abnormal tissues, and despite limited and carefully calculated treatment ports, significant irradiation of normal tissues is often unavoidable (2). RT-related complications

Fig. 1. Axial (A) and coronal (B) enhanced T1-weighted images (600/25) through the optic nerves and chiasm reveal enhancement of the right optic nerve immediately in the prechiasmic portion (white arrow). Notice the nerve is slightly enlarged as compared to the normal left side.



in the orbit, optic nerve, or chiasm can be divided into anterior or posterior lesions. Complications that occur anteriorly include irritation, erythema, and edema of the eyelid, xerophthalmia, nasolacrimal duct or sac stenosis with epiphora, conjunctivitis, keratitis, corneal ulceration, cataract, and ocular myositis (3). These complications are apparent clinically, acute vision loss is not the presenting complaint, and imaging studies are rarely needed for diagnosis.

Complications of the posterior compartment include retinal, optic nerve, and chiasm injury and may result in visual loss. Radiation-induced retinopathy likely result from vascular endothelial injury. On funduscopic examination, "cotton wool" spots, flame hemorrhages, hard exudates, neovascularity, and, ultimately, optic atrophy are seen (3).

Radionecrosis of the optic nerves and chiasm is a well-recognized, although uncommon, complication following therapeutic RT for lesions of the sella, parasellar region, paranasal sinuses, and skull base and has been reported to occur following RT for pituitary adenoma, craniopharyngioma, optic or hypothalamic glioma, meningioma, and nasopharyngeal and paranasal sinus carcinoma (1, 3-5). Radiation optic neuropathy, like radiation retinopathy, is likely related to total dose and daily fractionation size, with most cases occurring following 6000 cGy or more and a fractional dosage of greater than 200 cGy (3, 6). Following RT, peak occurrence is 1 to 1½ years, with most cases occurring within 3 years (1). Loss of vision is typically rapid, painless, and unilateral. If the anterior optic nerve is involved, disk edema will be seen acutely. If the posterior optic nerve is affected the disk will initially appear normal. As was the case in our series of patients, prognosis is poor, with most patients progressing to permanent visual loss in the affected eye and optic atrophy.

Although the pathogenesis of optic nerve damage is unclear, the microscopic appearance would suggest initial vascular injury that results in the perivascular inflammation, hyalinization, and fibrosis of vessel walls, loss of endothelium, and consequent infarction with reactive gliosis. Pathologic examination is usually not obtained in these individuals, as the presentation is often straightforward. However, in order to exclude recurrent adenoid cystic carcinoma, with its known propensity for perineural spread, one of the patients in this series underwent a biopsy of the enhancing portion of the optic nerve. This revealed perivascular inflammation, hyalinization, and fibrosis of vessel walls, consistent with radiation optic neuropathy.

Two of the patients in this series received chemotherapy prior to the course of RT. Systemic chemo-

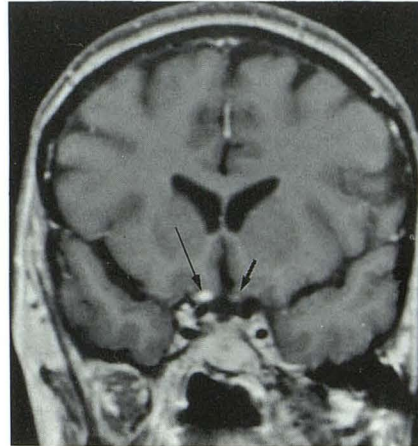

Fig. 2. Coronal enhanced T1-weighted image shows the normal nonenhancing prechiasmatic optic nerve on the left (*short black arrow*) and the enhancing right optic nerve (*long black arrow*).

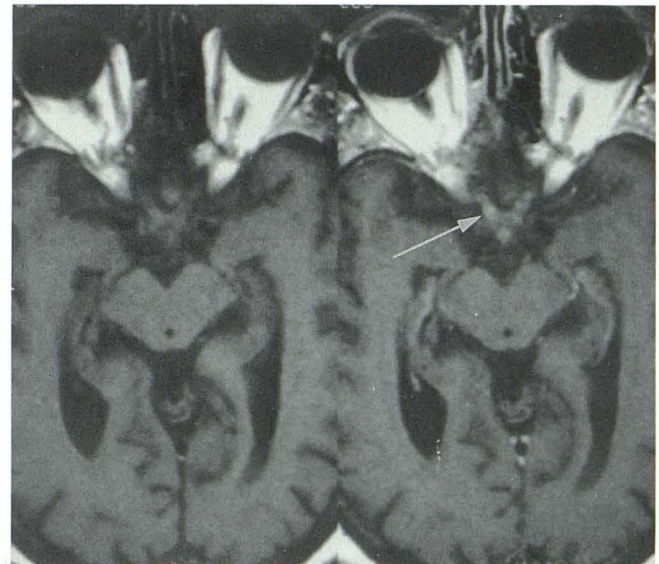


Fig. 3. Axial pre- (left) and postcontrast (right) T1-weighted images show discrete focal enhancement of the prechiasmatic right optic nerve (*white arrow*). Irregular enhancement is also noted in the left optic nerve.

therapy may contribute to the development of delayed radiation injury. Cerebral necrosis has been associated with radiotherapy and intraarterial, intrathecal or intravenous chemotherapy (7, 8). Experimentally, systemically administered mitotane potentiated the effects of radiation to the central nervous system in rats (9). Radiation optic neuropathy was reported in two patients who received low-dose prophylactic cranial radiation (2400 cGy) in conjunction with intrathecal chemotherapy (8). Two patients described by Guy et al (10) with radiation-induced optic neuropathy and enhancement of the intracranial optic nerves on MR had also received courses of chemotherapy.

Because of its superior soft tissue contrast and resolution about the skull base and sellar region as well as its multiplanar capabilities, MR has replaced computed tomography (CT) for detecting perisellar, perichiasmal masses as well as changes in architecture such as empty sella with prolapse of the chiasm (11). CT may reveal recurrent mass or tumor as the source of visual loss, but lacks the soft tissue contrast to routinely resolve subtle changes in the optic nerves or chiasm. Even with the addition of iodinated contrast, CT is usually normal in the setting of optic neuritis unless there is gross enlargement of the nerve. Recent studies suggest that enhanced MR, in the setting of optic neuritis or radiation optic neuropathy, may reveal abnormal enhancement within the affected nerve due to breakdown of the blood-brain barrier (6, 10, 12). We speculate that the injury that occurs with radiation optic neuropathy, specifically damage to vessel endothelium, results in the abnormal enhancement pattern seen in these patients. The degree of enhancement in radiation optic neuropathy appears more marked than optic nerve enhancement seen in optic neuritis due to demyelination; the primarily vascular insult may explain this differential in degree of enhancement.

All of our cases showed enhancement of the intracranial portions of the optic nerves that was easily visualized using routine spin echo-enhanced MR images. Unenhanced T1- and T2-weighted images were normal. No enhancing lesions were appreciated in the intraorbital optic nerves. However, techniques to suppress signal from fat were used in only one case, and enhancement in the intraorbital optic nerve could potentially have been missed in the other two patients. Recent reports demonstrate the advantages of fat suppression or saturation techniques for imaging the intraorbital optic nerves (13–15). With these techniques, signal from intraorbital fat and fat within the orbital bones at the orbital apex is suppressed, and enhancement, especially in the orbital optic nerve, becomes more conspicuous. If radiation optic neuritis is suspected, enhanced fat-suppressed T1-weighted images of the intraorbital optic nerve should be obtained. Enhancement in the intracranial optic nerve and chiasm is well visualized using routine enhanced T1-weighted sequences.

In conclusion, enhanced MR of the orbits, optic nerves, and chiasm is the imaging test of choice for the patient with vision loss following RT for skull base or sellar disease. Focal enhancement in an optic nerve that is normal in size or slightly enlarged may represent radiation optic neuropathy. These findings, in the correct clinical setting, may obviate the need for biopsy.

## References

1. Kline LB, Kim JY, Ceballos R. Radiation optic neuropathy. *Ophthalmology* 1985;92:1118–1126
2. Wang CC. Complications of radiation therapy. In: Wang CC, ed. *Radiation therapy for head and neck neoplasms*. Boston: John Wright PSG, 1983;297–300
3. Nakissa N, Rubin P, Strohl R, Keys H. Ocular and orbital complications following radiation therapy of paranasal sinus malignancies and review of literature. *Cancer* 1983;51:980–986
4. Roden D, Bosley TM, Fowble B, et al. Delayed radiation injury to the retrobulbar optic nerves and chiasm: clinical syndrome and treatment with hyperbaric oxygen and corticosteroids. *Ophthalmology* 1990;97:346–351
5. Kinyoun JL, Kalina RE, Brower SA, Mills RP, Johnson RH. Radiation retinopathy after orbital irradiation for Graves' ophthalmopathy. *Arch Ophthalmol* 1984;102:1473–1476
6. Zimmerman CF, Schatz NJ, Glaser JS. Magnetic resonance imaging of radiation optic neuropathy. *Am J Ophthalmol* 1990;110:389–394
7. Di Chiro G, Oldfield E, Wright DC, et al. Cerebral necrosis after radiotherapy and/or intraarterial chemotherapy for brain tumors: PET and neuro-pathologic studies. *AJNR* 1987;8:1083–1091
8. Fishman ML, Bean SC, Cogan DG. Optic atrophy following prophylactic chemotherapy and cranial radiation for acute lymphocytic leukemia. *Am J Ophthalmol* 1976;82:571–576
9. Glicksman AS, Bliven SF, Leith JT. Modification of radiation damage in rat spinal cord by Mitotane. *Cancer Treat Rep* 1982;66:1545–1547
10. Guy J, Mancuso A, Quisling RG, Beck R, Moster M. Gadolinium-DTPA-enhanced magnetic resonance imaging in optic neuropathies. *Ophthalmology* 1990;97:592–600
11. Kaufman B, Tomsak RL, Kaufman BA, et al. Herniation of the suprasellar visual system and third ventricle into empty sellae: morphologic and clinical considerations. *AJNR* 1989;10:65–76
12. Guy J, Mancuso A, Beck R, et al. Radiation-induced optic neuropathy: a magnetic resonance imaging study. *J Neurosurg* 1991;74:426–432
13. Simon J, Szumowski J, Totterman S, et al. Fat-suppression MR imaging of the orbit. *AJNR* 1988;9:961–968
14. Hendrix LE, Kneeland, JB, Haughton VM, et al. MR imaging of optic nerve lesions: value of gadopentetate dimeglumine and fat-suppression technique. *AJNR* 1990;11:749–754
15. Tien RD, Chu PK, Hesselink JR, Szumowski J. Intra- and paraorbital lesions: value of fat-suppression MR imaging with paramagnetic contrast enhancement. *AJNR* 1991;12:245–253