

Are your **MRI contrast agents** cost-effective?

Learn more about generic **Gadolinium-Based Contrast Agents**.



FRESENIUS
KABI

caring for life

AJNR

Globe tenting: a sign of increased orbital tension.

R W Dalley, W D Robertson and J Rootman

AJNR Am J Neuroradiol 1989, 10 (1) 181-186

<http://www.ajnr.org/content/10/1/181>

This information is current as
of June 30, 2024.

Globe Tenting: A Sign of Increased Orbital Tension

Robert W. Dalley^{1,2}
William D. Robertson¹
Jack Rootman³

Globe tenting is a change in the posterior globe configuration that results in a tented or conical appearance and is objectively defined as a posterior globe angle of less than 130°. Globe tenting is caused by an acute/subacute intraorbital mass effect producing significant proptosis with tethering of the globe by the stretched optic nerve. In this series of 10 patients, globe tenting was produced by subperiosteal abscess (five cases), hemorrhage into a lymphangioma (two cases), a varix (one case), traumatic carotid cavernous fistula (one case), and multiple epithelial implantation cysts (one case). Progressive narrowing of the posterior globe angle correlated with an increase in proptosis and in optic nerve length, as well as with more severe visual impairment. Tenting with a posterior globe angle of 120–130° correlated with mild visual symptoms and a good recovery. A posterior globe angle of less than 120° with acute proptosis constitutes a surgical emergency; a delay in surgical decompression in these patients may prevent complete recovery of visual function.

CT is useful in providing good characterization of globe tenting and, thus, in helping to determine the clinical significance of this abnormality.

CT of patients with proptosis commonly demonstrates stretching of the optic nerve associated with the axial displacement of the globe, yet most of these globes maintain a spherical contour. We have noted several cases with high-grade proptosis in which the posterior globe margins develop a conical shape. We have coined the term "globe tenting" to describe this configuration. Most of these patients have some degree of ocular sensorimotor and/or visual impairment, some with complete loss of vision. Although cases of high-grade proptosis with the configurational change of globe tenting have been described in the literature, no specific description, comment, or analysis of this sign has been reported to our knowledge [1–7]. The purpose of this study is to characterize this abnormality and determine its clinical significance.

Materials and Methods

A review of high-resolution orbital CT scans performed since 1980 yielded 10 cases with a specific configurational change in the posterior globe. All orbital scans were acquired on a GE 8800 or 9800 scanner with 5- or 3-mm-thick axial sections, respectively. The axial scanning angle was +10–15° off the orbitomeatal line, parallel to the optic canals and nerves. Coronal imaging was also performed in most cases, but this plane was not found useful in evaluating globe tenting. All measurements were made on hardcopy images magnified two times.

The study was divided into two phases. In the first phase, objective measurements for the posterior globe were devised by defining (1) a posterior globe angle and (2) an optic nerve ratio, with the subsequent establishment of normal values for each. The posterior globe angle is measured by drawing tangents to the medial and lateral aspects of the sclera at the optic nerve insertion (Fig. 1A). Sixty-two normal orbits were evaluated. The optic nerve ratio, defined as the ratio of the optic nerve length in the abnormal orbit divided by the optic nerve length of the contralateral normal eye, was measured in 25 pairs of normal orbits. The optic

Received September 8, 1987; accepted after revision May 26, 1988.

¹ Department of Radiology, University of British Columbia and Vancouver General Hospital, Vancouver, B.C., Canada V5Z 1M9.

² Present address: Department of Radiology, SB-05, University of Washington, 1959 N.E. Pacific St., Seattle, WA 98195. Address reprint requests to R. W. Dalley.

³ Department of Ophthalmology, University of British Columbia and Vancouver General Hospital, Vancouver, B.C., Canada V5Z 1M9.

AJNR 10:181–186, January/February 1989
0195–6108/89/1001–0181

© American Society of Neuroradiology

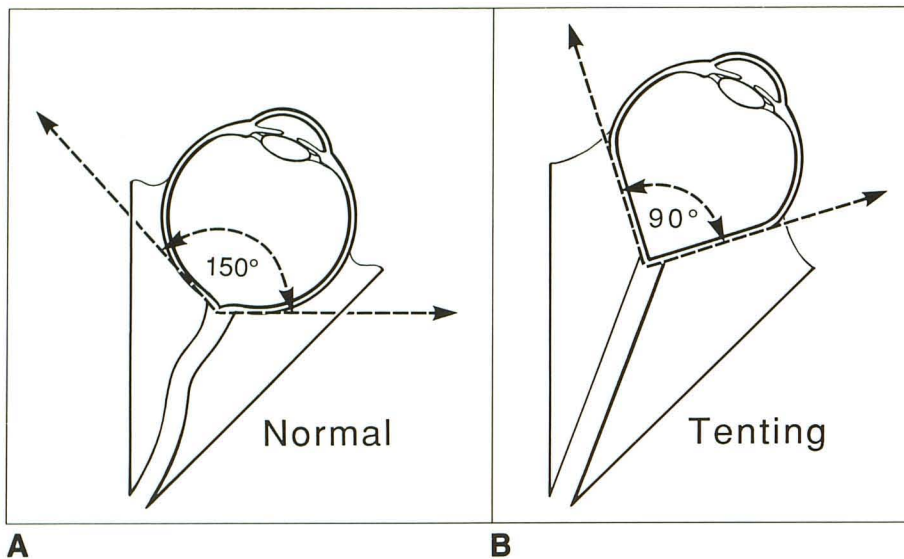


Fig. 1.—A, Diagram of normal orbit shows spherical globe. Tangents (dotted lines) are drawn from medial and lateral aspects of posterior globe margin at the optic nerve insertion. The angle formed by these lines is the posterior globe angle, which normally measures 150°.

B, Diagram of an orbit with globe tenting shows axial proptosis of the eye, stretching of the optic nerve, and flattening of the medial and lateral margins of the posterior globe. The posterior globe angle (dotted lines) has narrowed. Posterior globe angles less than 130° are abnormal and indicate globe tenting.

nerve length is measured from the anterior end of the optic canal at the orbital apex to its insertion into the globe on a single section, or on two contiguous sections, which approximates the true length of the mildly undulating nerves. In normal orbits, this ratio should equal 1.00.

In the second phase of the study, globe tenting was defined as a posterior globe angle of less than 130° (Fig. 1B), with 10 cases fulfilling this requirement. Globe tenting was divided into mild grade-1 (posterior globe angle between 120–130°) and severe grade-2 (posterior globe angle of less than 120°) categories.

The optic nerve ratio and degree of proptosis were measured in each case. Proptosis is defined as the difference in millimeters in the position of the posterior aspect of the affected versus the unaffected globe relative to the interzygomatic line at the level of the lens [8]. Axial globe lengths were measured in each case and all showed 1–2-mm differences, but the ratios were quite variable and therefore not included in this study. Orbital mass lesions were described as intraconal, extraconal, or both.

Clinical data included age, gender, diagnosis, duration of symptoms prior to the CT scan, visual acuity of the affected eye at the time of the CT, presence of an afferent pupillary defect, and follow-up visual acuity after treatment. The incidence and significance of globe tenting were reviewed in the orbital referral population at Vancouver General Hospital, which included 1264 cases.

Results

The normal posterior globe angle has a mean of 150° with a range ($n = 62$) of 134–164°. From these figures, we defined values of the posterior globe angle of less than 130° as abnormal. The optic nerve ratio had a mean of 1.03, which is close to the expected value of 1.00. Ratios greater than 1.1 were defined as abnormal. Optic nerve lengths (corrected for magnification) averaged 30 mm in normal adults. Children had a wide range of lengths, depending on their age. Table 1 summarizes the normal values of these measurements.

The results obtained from the 10 globe tenting patients are given in Table 2. Four had mild (grade-1) tenting (Fig. 2A) and six had severe (grade-2) tenting (Fig. 2B). The posterior angle ranged from the mildest (124°) to the narrowest and most

TABLE 1: Normal Orbital Measurements

	No.	Mean	Normal (2 Standard Deviations)
Posterior globe angle (degrees)	62	150	136–164
Optic nerve length in adults (mm)	40	30	25–35
Optic nerve ratio*	25	1.03	0.97–1.09

* Optic nerve ratio equals the ipsilateral affected optic nerve length divided by the contralateral normal nerve length.

severe (87°). The optic nerve ratio ranged from 1.1–1.3 in the grade-1 tenting patients, except for patient 4 (Fig. 3), who had a ratio of 1.7 before and after hemorrhage. The grade-2 tenting patients showed ratios between 1.3–1.7. Proptosis varied from 0–12 mm in grade-1 tenting (12 mm before and after hemorrhage in patient 4) and from 10–15 mm in grade-2 tenting. As would be expected, the ratio of optic nerve lengths and degree of proptosis correlated well. In general, globe tenting became more prominent as the optic nerve ratio and proptosis increased, again with the exception of patient 4, who had a preexisting lymphangioma and developed an acute hemorrhage.

Globe tenting in this series was produced by the following processes: subperiosteal abscess (five cases), hemorrhage into a lymphangioma (2 cases), a varix (one case), traumatic carotid cavernous fistula (one case), and multiple epithelial implantation cysts (one case). Both lymphangiomas were completely intraconal. The carotid cavernous fistula and the case of multiple epithelial implantation cysts (which were postsurgical or traumatic epithelial cysts) had diffuse intraconal and extraconal involvement. Both lymphangiomas and the case of multiple implantation cysts (Fig. 4) showed an intraconal component of the lesion abutting the posterior globe. The five subperiosteal abscesses and the varix were entirely extraconal and had no direct impingement on the globe.

TABLE 2: Clinical Data and CT Measurements in 10 Globe Tenting Cases

Case No.	Gender	Age	Diagnosis	Duration of Symptoms	Pretreatment Vision	Posttreatment Vision	Grade of Tenting	Posterior Globe Angle	Optic Nerve Ratio	Proptosis (mm)	Intra- vs Extraconal
1	M	7	Subperiosteal abscess	2 days	20/70	20/20	1	124	1.3	7	E
2	M	14	Orbital varix	1 month	20/70	20/20	1	123	1.1	0	E
3	M	9	Subperiosteal abscess	2 days	20/60	20/20	1	123	1.3	5	E
4	F	3	Hemorrhage into lymphangioma	1 day	20/400	20/25	1	121	1.7	9	I
5	M	20	Multiple implantation cysts	3-4 months	20/200*	20/80	2	119	1.3	7	E/I
6	M	34	Subperiosteal abscess	2 months	No light*	No light	2	117	1.4	7	E
7	F	61	Subperiosteal abscess	3-6 hr	No light*	No light	2	107	1.4	7	E
8	M	49	Subperiosteal abscess	2 weeks	20/50*	20/20	2	103	1.3	7	E
9	M	42	Traumatic carotid cavernous fistula	20 days	No light*	No light	2	102	1.4	11	E/I
10	M	2	Hemorrhage into lymphangioma	7 days	Not measured	20/20	2	87	1.7	11	I

* Afferent pupillary defect.

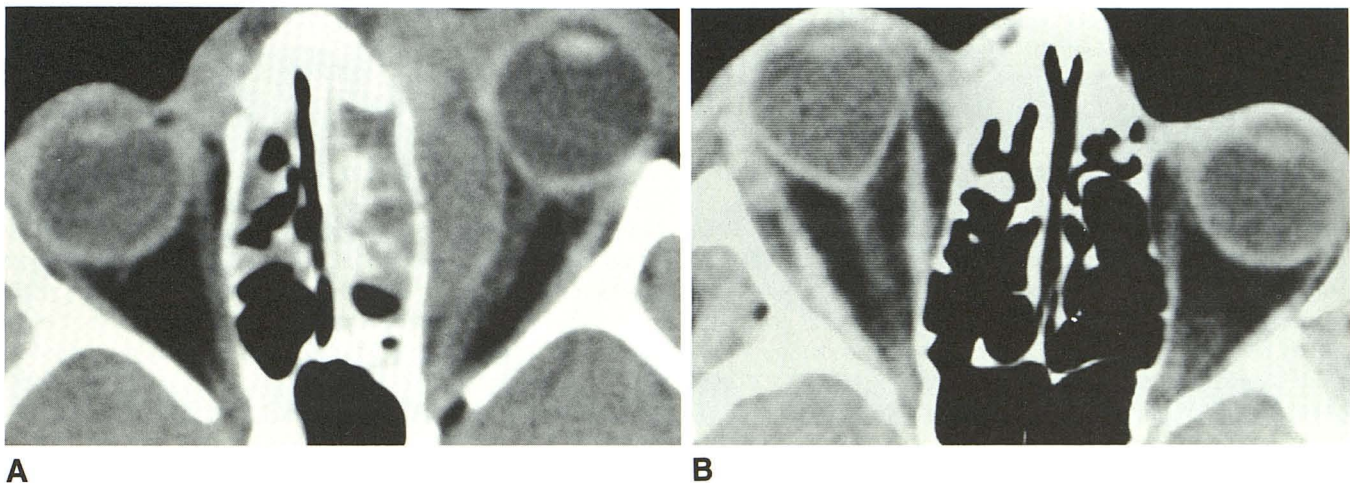


Fig. 2.—A, Axial noncontrast CT scan of 7-year-old boy (case 1) with fever and progressive left proptosis developing over 2 days demonstrates opacification of the left ethmoid sinus complex. An associated soft-tissue mass displaces the medial rectus causing mild proptosis. Diagnosis: subperiosteal abscess with mild grade-1 tenting.

B, Axial noncontrast CT scan of 61-year-old woman (case 7) with fever and rapidly developing right proptosis over a few hours. Frontal sinus opacification and subperiosteal fluid collection under orbital roof (not shown) are associated with high-grade proptosis and severe narrowing of the posterior globe angle. Diagnosis: subperiosteal abscess with severe grade-2 globe tenting.

Eight patients were male and two were female. The overall age range was 2–61 years, with a mean of 21 years. Patients with grade-1 tenting ranged in age from 3 to 14 years (mean age, 8 years); those with grade-2 tenting ranged from 2 to 61 years (mean age, 34 years). The duration of symptoms prior to CT ranged from 6 hr to 2 months, although onset of proptosis was usually the deciding factor in obtaining orbital CT.

In the four grade-1 (mild) globe tenting patients, three showed mild impairment of visual acuity. The fourth patient with a chronic lymphangioma and a superimposed acute

hemorrhage had severe impairment of visual acuity without an afferent defect. None of the grade-1 cases had an afferent pupillary defect. After treatment, vision in all four patients returned to normal or near normal.

In the six patients who had grade-2 (severe) globe tenting, one had mild visual impairment, one had moderate visual impairment, three had no light perception, and the last one was not tested (case 10, a 2-year-old boy). All five who were tested had afferent pupillary defects. In two of the grade-2 cases, vision completely returned to normal after treatment, one had moderate visual impairment after treatment (case 5,

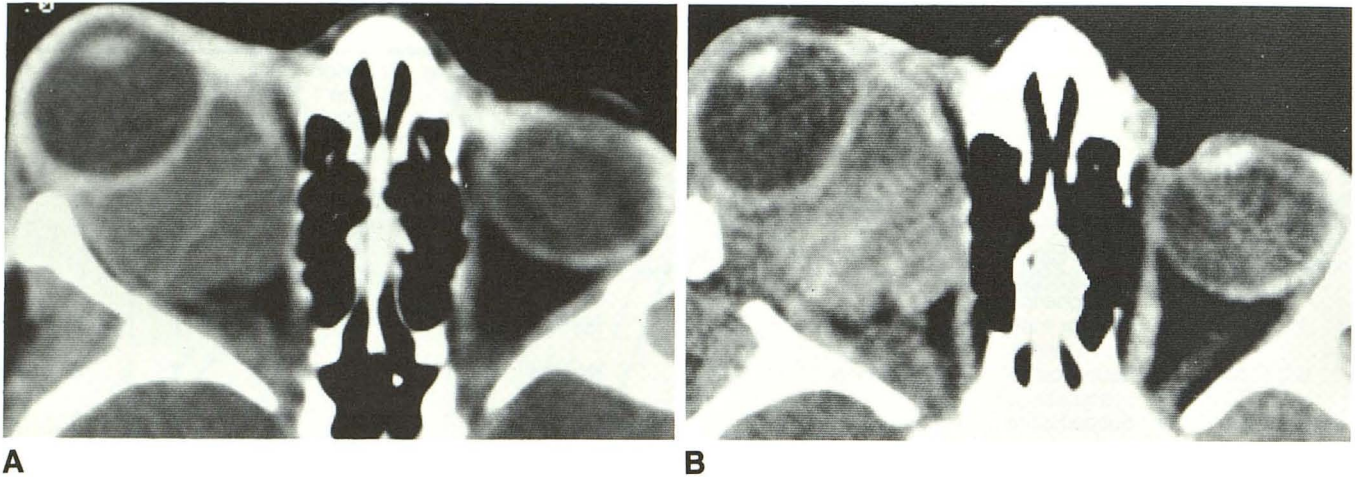


Fig. 3.—A, Axial contrast-enhanced CT scan of 3-year-old girl (case 4) with severe chronic right proptosis. A homogeneous nonenhancing intraconal mass surrounds and conforms to the right globe, but the posterior margin of the eye remains spherical. Diagnosis: chronic lymphangioma with no globe tenting.

B, Axial noncontrast CT scan 1 day after a spontaneous hemorrhage into lymphangioma (7 days after first CT, Fig. 3A) now shows high-density hemorrhage within intraconal mass. Note configurational change of the posterior globe with narrowing of the posterior globe angle. Diagnosis: lymphangioma with superimposed acute hemorrhage and mild grade-1 globe tenting.

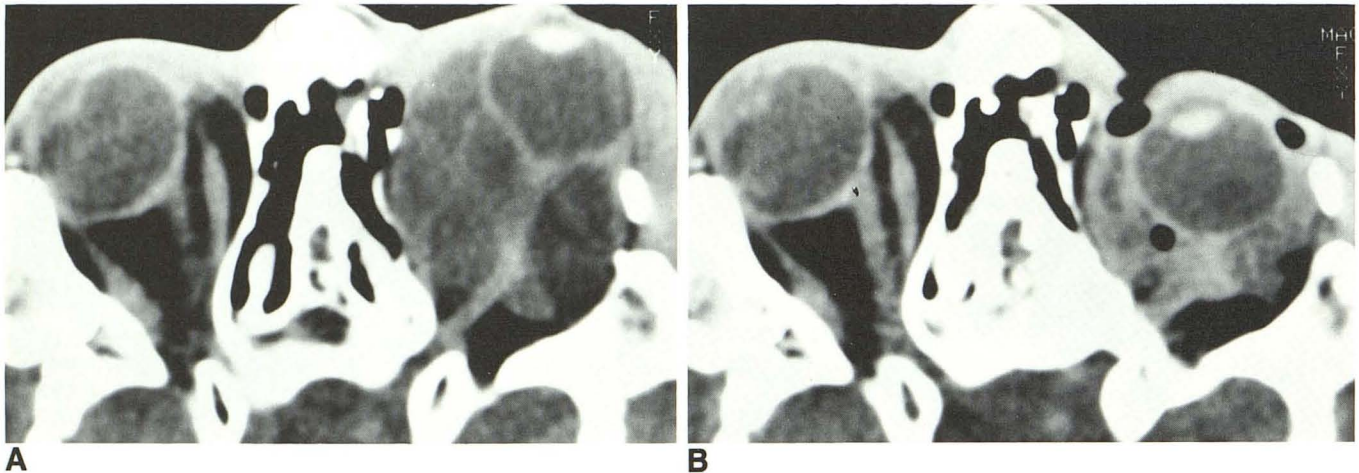


Fig. 4.—A, Axial noncontrast CT scan of 20-year-old man (case 5) with a history of multiple craniofacial reconstructions. A low-density cystic septated mass involving the intraconal and extraconal spaces is causing proptosis and narrowing of the posterior globe angle. Diagnosis: multiple postsurgical epithelial implantation cysts with severe grade-2 globe tenting.

B, Axial noncontrast CT scan immediately after needle aspiration shows the globe has returned to normal with nearly complete resolution of globe tenting.

multiple epithelial implantation cysts), and two of these three were younger than 20 years old. In the three who presented with no light perception, all were over 20 years old and all remained blind in the affected eye despite treatment. However, the blindness in the patient with traumatic carotid cavernous fistula was related to an associated ocular injury.

A total of 12% (157/1264) of referral patients had catastrophic (less than 24 hr) or acute (within days) onset of proptosis. Seven percent (11/157) of these catastrophic and acute cases had globe tenting. The majority (93%) of the 157 cases had no evidence of tenting. (Note: Since reporting these 10 cases of tenting, an 11th case presented with tenting due

to tension pneumo-orbita.) Of the 46 orbital cellulitis/subperiosteal abscess cases we reviewed, 11% (5/46) had tenting.

Discussion

Proptosis may develop slowly from a variety of focal or diffuse orbital lesions. A focal mass (e.g., hemangioma) or a diffuse infiltrative process (e.g., thyroid ophthalmopathy) slowly occupies space in the orbit resulting in axial displacement of the orbital contents and lengthening of the optic nerve without an acute increase in orbital tension. On the other hand, a subperiosteal abscess or an orbital hemorrhage rap-

idly occupies the orbital space, acutely increasing the orbital tension and displacing the globe along with other soft tissues. The normal slightly redundant optic nerve must straighten and stretch in response to the acute anterior globe displacement. Increases in the optic nerve length, optic nerve ratio, and degree of proptosis are all indices of axial globe displacement and were generally proportional to the severity of globe tenting in this study. When all causes and severities of proptosis are considered, neither the optic nerve length, optic nerve ratio, nor the degree of proptosis necessarily predicts the chronicity of the displacement or the loss of visual function. However, globe tenting reflects the acuteness of proptosis and predicts visual compromise.

Globe tenting is always accompanied by proptosis but also requires an acute or subacute intraorbital mass effect and increased orbital tension. We believe globe tenting is the end result of acute anterior displacement of the eye. The limited stretch of the optic nerve tethers the globe, flattens the curvature of the posterior globe margin, narrows the posterior globe angle, and mildly lengthens the globe itself. The posterior globe then assumes the shape of a cone with the optic nerve at its apex. If axial displacement of the globe develops slowly, the optic nerve and orbital-septal complex have time to accommodate and the posterior globe margin remains spherical. Acute displacements do not allow such accommodation so the posterior globe must lengthen as well, resulting in globe tenting.

Direct indentation of the globe can occur acutely or chronically from anteriorly located intraconal or extraconal masses. An acute anterior intraconal mass (e.g., hemorrhage into a retrobulbar lymphangioma) can directly impinge on the posterior globe, but it is the concomitant acute increase in proptosis and stretching of the optic nerve that tents the posterior globe. In our experience none of the chronic orbital mass lesions, either intraconal or extraconal, have produced the flattened configurational change on both the medial and lateral aspects of the posterior globe margin, which typifies globe tenting. (We find chronic lesions may abut the posterior globe margin but the eye usually remains spherical. If a chronic mass does indent the globe, the indentation follows the surface configuration of the tumor but does not affect the posterior globe angle. A combined effect of direct indentation and acute orbital tension may contribute to tenting in a few cases, but we feel the majority of the tenting is from the increased orbital tension.) A chronic mass distant from the globe in the orbital apex or a chronic process (e.g., thyroid ophthalmopathy) would not likely cause globe tenting. On the other hand, our review shows globe tenting can be produced by an acute mass distant from the globe (e.g., subperiosteal abscess) or by an acute diffuse lesion (e.g., carotid cavernous fistula). Inflammatory processes such as intraconal orbital cellulitis may cause thickening and enhancement of the scleral and episcleral tissues, but we can only speculate whether this prevents globe tenting. All five inflammatory lesions in our review were subperiosteal (i.e., extraconal) abscesses.

Globe tenting was always seen with an acute or subacute process, but the number of tenting cases is low. We cannot

say it is an invariable sign of an acute or subacute mass. As demonstrated by the variety of etiologies, it is not a specific sign of a particular disease, but it is a sign we saw only in the tense orbit. The majority (93%) of patients who had acute or subacute orbital masses did not have the globe tenting sign. A possible explanation is that these patients may have a longer redundant nerve and thus are less susceptible to the tenting process, or perhaps the acute tension was simply less severe. Although tenting is not the usual presentation of an acute orbital mass, it may imply disastrous consequences if treatment is delayed.

A further objective of the study was to determine if a correlation exists between the clinical outcome and degree of globe tenting. In general, the grade-1 (mild) globe tenting patients had milder compromise of visual acuity, no afferent pupillary defect, and recovered completely with treatment. The grade-2 (severe) globe tenting patients presented with severe compromise of visual acuity or blindness and had afferent pupillary defects. Recovery of vision in this group was more variable. Three remained blind. Improvement in the other three was attributed either to rapid decompression or resection of the lesion or to the younger age of the patient. In both groups the younger patients recovered more completely.

An ophthalmologist's decision to operate is based on a combination of three criteria: (1) the catastrophic nature of the event; (2) clinical evidence of extreme orbital tension, including a firm globe, raised intraocular pressure, marked restriction of ocular movement, reduction in vision, corneal exposure, and an afferent pupillary defect (fundoscopy may reveal a raised optic disk [papilledema], flattening of the posterior globe, and evidence of acute choroidal striae); and (3) CT evidence of orbital tension and/or globe tenting. Since these are usually emergency situations and occur frequently in young children who may have difficulty in responding to psychophysical testing, the radiologist's input based on an orbital CT scan that shows globe tenting may be quite valuable in suggesting the urgency of decompression in these cases.

The mechanism of visual compromise in the globe tenting patients is interesting to consider. Chronic proptosis can produce severe axial displacement of the globe with associated lengthening of the optic nerve with little if any compromise of vision. Presumably, the preservation of optic nerve function is related to the optic nerve's ability to accommodate to the stretching. The optic nerve ratio and degree of proptosis, therefore, do not correlate with optic nerve functional compromise. The optic nerve damage and functional loss in this series may have developed acutely from (1) direct trauma or contusion (traumatic carotid cavernous fistula); (2) direct compression, particularly in the orbital apex (subperiosteal abscess); (3) direct intraconal compression (multiple epithelial implantation cysts); (4) acute optic nerve stretching alone; or (5) ischemia of the optic nerve [1]. Arterial insufficiency or venous stasis may be contributing factors in these cases [9]. We postulate that patients with mild globe tenting recovered either because they had only a minimal amount of tension,

pressure, or ischemia affecting the optic nerve or because of the rapid correction of the insult before permanent damage could occur. The younger patients with severe globe tenting seemed to tolerate the insult better than those in the older age group. Moreover, the older patients presented with more severe visual loss and responded less well to treatment. Whatever the cause, failure to treat the process rapidly may result in permanent visual dysfunction.

In summary, globe tenting is defined by narrowing of the posterior globe angle to less than 130° ; it is accompanied by acute proptosis and is caused by acute intraorbital mass effect. Globe tenting is a sign of acute or subacute orbital tension, most often caused by a subperiosteal abscess or a hemorrhage into a preexisting lesion. Globe tenting patients with a posterior globe angle of $120\text{--}130^\circ$ had mild visual dysfunction and good recovery after treatment. We believe that a posterior angle of less than 120° constitutes a surgical emergency requiring intervention to preserve visual function.

REFERENCES

1. Leo JS, Halpern J, Sackler JP. Computed tomography in the evaluation of orbital infections. *Comput Tomogr* **1980**;4:133-138
2. Bilaniuk LT, Zimmerman RA. Computer-assisted tomography: sinus lesions with orbital involvement. *Head Neck Surg* **1980**;2:293-301
3. Goodwin WJ Jr, Weinshall M, Chandler JR. The role of high resolution computerized tomography and standardized ultrasound in the evaluation of orbital cellulitis. *Laryngoscope* **1982**;92:728-731
4. Gonzales CF, Becker MH, Flanagan JC. *Diagnostic imaging in ophthalmology*. New York: Springer-Verlay, **1986**:314-316
5. Hammerschlag SB, Hesselink JR, Weber AL. *Computerized tomography of the eye and orbit*. Norwalk, CN: Appleton-Century-Crofts, **1983**: 179-181
6. Trokel SL. Computed tomographic scanning of orbital inflammations. *Int Ophthalmol Clin* **1982**;22:81-98
7. Spencer WH, ed. *Ophthalmologic pathology: an atlas and textbook*, vol. 3, 3rd ed. Philadelphia: Saunders, **1986**:2368-2457, 2812-2831
8. Peyster RG, Hoover E. *Computerized tomography in orbital disease and neuroophthalmology*. Chicago: Year Book Medical, **1984**:8, 15
9. Kronschnabel EF. Orbital apex syndrome due to sinus infection. *Laryngoscope* **1974**;84:353-362