

The **next generation** GBCA
from Guerbet is here

Explore new possibilities >

Guerbet | 

© Guerbet 2024 GUOB220151-A

AJNR

Intermittent occlusion of internal carotid artery by hypoglossal nerve.

M Henne, J U Morano and W F Russell

AJNR Am J Neuroradiol 1988, 9 (4) 791-793

<http://www.ajnr.org/content/9/4/791.citation>

This information is current as
of September 28, 2024.

Intermittent Occlusion of Internal Carotid Artery by Hypoglossal Nerve

Manfred Henne,¹ James U. Morano, William F. Russell

The case reported here demonstrates intermittent, total occlusion of the internal carotid artery and occipital artery with head and neck rotation and extension. We believe the close proximity of the crossing hypoglossal nerve was the major cause.

Case Report

A 51-year-old man experienced the onset of positionally dependent neurologic changes. When he turned his head to the left and extended his neck for longer than 3 sec he became dizzy and experienced a sensation of "numbness" over his right body, including his face. This was accompanied by loss of motor control of the right body. He had some blurring of vision during these episodes but no loss of consciousness and no associated headache.

A CT scan demonstrated an area of infarction in the left parieto-occipital region. A conventional cerebral arteriogram performed with the head in a neutral position (Fig. 1) was unremarkable except for the presence of an incomplete circle of Willis. The horizontal segment of the right anterior cerebral artery never opacified, and both pericallosal arteries opacified on the left common carotid artery injection. Subsequently, several left carotid injections were repeated with the patient performing the head maneuver that provoked his symptoms (head turned toward the left with extension of the neck; Fig. 2). Depending on the degree of rotation of the head and extension of the neck, there was partial or total occlusion of the left internal carotid artery about 4 cm above the common carotid bifurcation. This occurred at approximately the level of the adjacent occipital artery coursing posteriorly, and seemed to be caused by an extrinsic pressure effect. On one of the injections (not shown), occlusion of the occipital artery also occurred. There was no abnormal course or elongation of the internal carotid artery, which could have been responsible for this finding.

At surgery the hypoglossal nerve and the occipital branch of the external carotid artery were found to be intertwined in such fashion that the hypoglossal nerve was pulled taut and stretched against the adjacent internal carotid artery when the head was hyperextended and turned to the ipsilateral side. The internal carotid artery was also noted to bear a small indentation at this level where chronic compression by the hypoglossal nerve had occurred (Fig. 3). Consequently, external compression by the hypoglossal nerve was believed to be responsible for the intermittent occlusive changes in the internal carotid artery.

The occipital artery was clamped and divided, thus releasing some of the tension of the hypoglossal nerve on the internal carotid artery. The patient did well postoperatively and seemed to be relieved from his symptoms on short-term follow-up.

Discussion

To our knowledge this is the first case reported of its kind. The findings are remarkable because of the congenital "anomalous" relationship of internal carotid artery, occipital artery, and hypoglossal nerve that can conceivably cause serious neurologic changes, and because the relatively simple surgical procedure of dividing the occipital artery was able to relieve the symptoms. It is well recognized that blood flow in the carotid or vertebral artery can be decreased if the neck is turned to one side [1, 2]. These changes in flow in one vessel seem to be well compensated by increased collateral flow within the circle of Willis, and thereby total cerebral blood flow remains relatively constant [2]. Intermittent cerebral ischemia with symptoms may, however, develop with an incomplete circle of Willis if the reduction of flow is below a critical level with head rotation.

Mauersberger [3] reported on a 30-year-old man with position-dependent ischemia combined with a hypoglossus paresis, which, he postulated, was caused by a pressure effect on the nerve by an angiographically demonstrated tight coiling of the right internal carotid artery. This, however, was not proved surgically. Nevertheless, it suggests that the relationship of the carotid and hypoglossal nerve may be critical to either the nerve or the vessel under certain circumstances. Peripheral hypoglossal nerve paralysis can occur from compression by vascular structures such as loops of the internal carotid artery, lateral position of the external carotid artery, or aneurysm of the internal carotid artery [4–9]. In the case reported here, no specific pathologic process caused the intermittent occlusion of the internal carotid artery. Instead, we believe it was simply the anatomic variation of the proximity of the internal carotid artery, the crossing hypoglossal nerve, and the snaring occipital artery that were responsible.

Received December 11, 1986; accepted after revision February 1, 1987.

Presented in part at the annual meeting of Southeastern Neuroradiologists, Sea Island, GA, September 1986.

¹ All authors: Department of Radiology, University of Mississippi Medical Center, Jackson, MS 39216-4505. Address reprint requests to J. U. Morano.

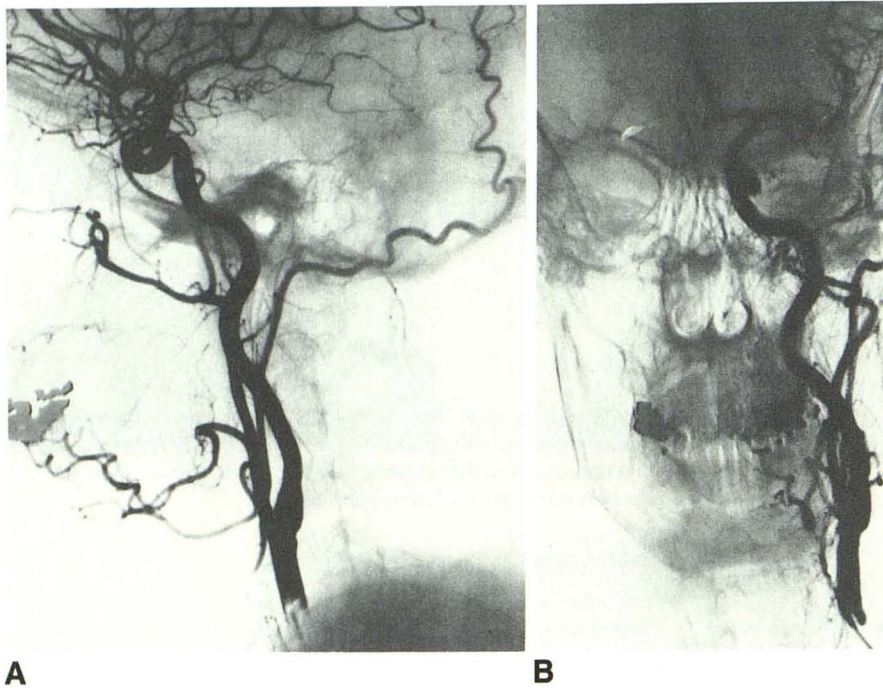


Fig. 1.—Lateral (A) and anteroposterior (B) arteriograms of left common carotid artery injection with head and neck in neutral position. No abnormalities are seen.

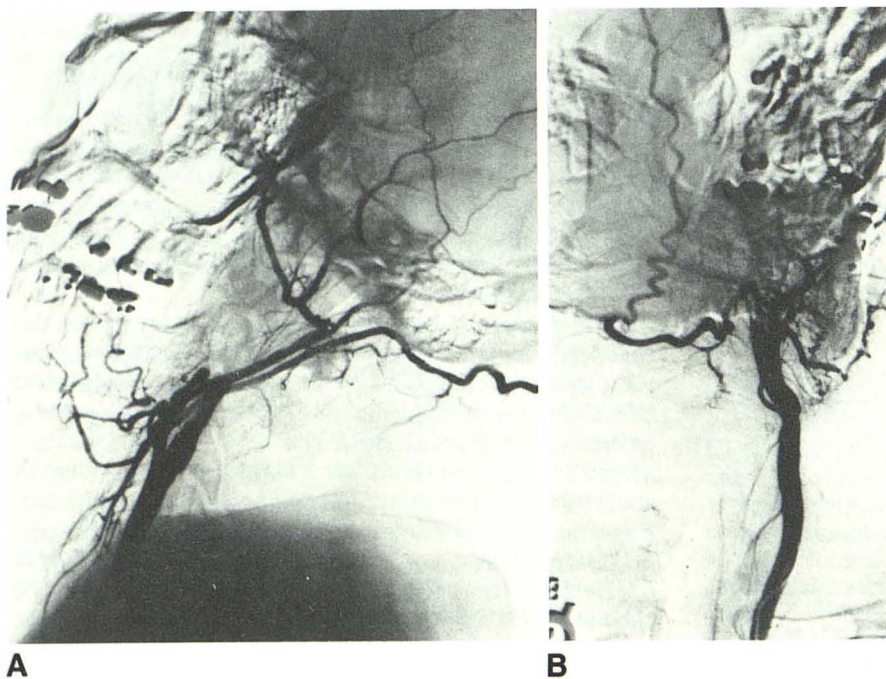


Fig. 2.—A and B, Biplane arteriograms of left common carotid artery injection with head turned and neck hyperextended. Total occlusion of internal carotid artery is revealed.

Three main types of variations in the relationship of the occipital artery and hypoglossal nerve have been described according to the level at which the nerve crosses the external carotid artery and the point of origin of the occipital artery [10]. In this case the anatomy corresponds to the so-called type-III orientation in which the occipital artery originates from the external carotid artery below the level at which the hypoglossal nerve crosses the external carotid artery. The occipital artery courses superiorly and arches posteriorly around the nerve, passing first medially and continuing superiorly and

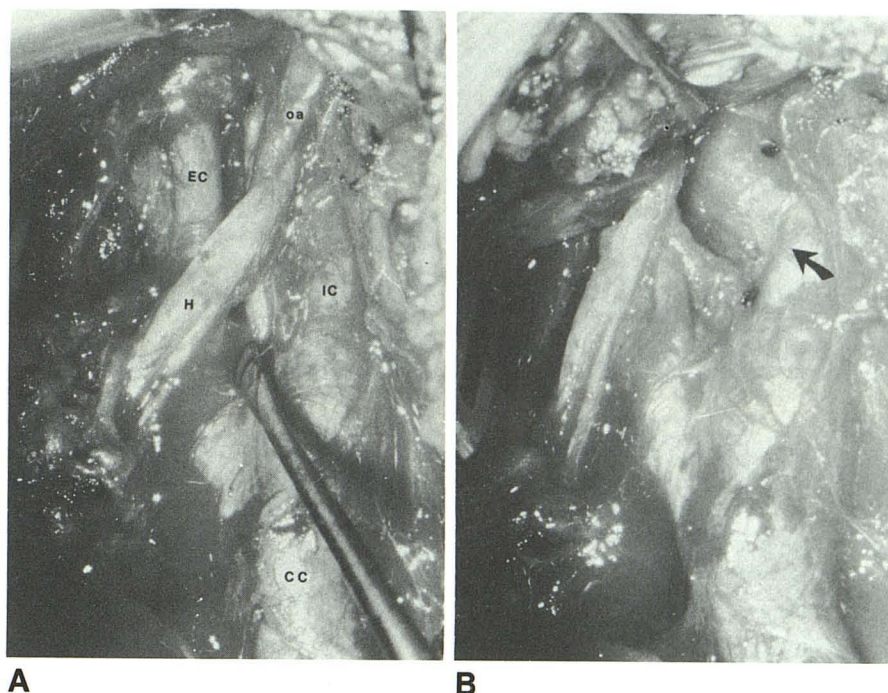
laterally to it. From there the occipital artery courses along the inferior border of the posterior belly of the digastric muscle.

Nathan and Levy [10] postulate a developmental mechanism in which the arched hypoglossal nerve moves progressively upward in relation to the lateral aspect of the external carotid artery. If, as in this case, the nerve ascends higher than the origin of the occipital artery, the latter is caught and pulled by the nerve and is forced to follow an arched course around the nerve. Branches of the occipital artery, such as

Fig. 3.—Intraoperative photographs.

A, CC = common carotid artery, IC = internal carotid artery, EC = external carotid artery, oa = occipital artery, and H = hypoglossal nerve.

B, Retraction of hypoglossal nerve reveals underlying indentation (arrow) of internal carotid artery, which was believed to be the level of intermittent occlusion.



the sternocleidomastoid artery, can also be caught by the nerve. In this way the nerve appears entrapped by the loop of the occipital artery, and, if sufficiently tight, there will be a pressure effect between the nerve and occipital artery.

The ascension of the arching nerve may be explained by a relative shortening of the nerve compared with the vessels. In the type-III orientation the loop of the occipital artery limits the upward movement of the nerve and therefore the shortening process must result in a more medial location of the nerve. It would seem that this was probably the situation in our case, considering the lateral indentation on the internal carotid artery caused by the laterally crossing nerve.

In conclusion, neurologic symptoms produced by acute head rotation can be caused by intermittent total occlusion of the internal carotid artery. Stroke, embolic phenomenon, and thrombosis may be especially threatening when an incomplete circle of Willis is present. Angiography is the diagnostic procedure of choice. It should be stressed that angiography in the neutral head and neck position may miss the stenosis, angulation, or occlusion of the internal carotid artery. Therefore, in patients who complain that their neurologic symptoms are aggravated by changes in head position, an effort should be made to reproduce these positional changes during angiography.

REFERENCES

1. Toole JF, Tucker SH. Influence of head position upon cerebral circulation. Studies on blood flow in cadavers. *Arch Neurol* 1960;2:616-623
2. Hardesty WH, Roberts B, Toole JF, Royster HP. Studies of carotid-artery blood flow in man. *N Engl J Med* 1960;263(19):944-946.
3. Mauersberger W. Cerebrale Durchblutungsstörungen und Parese des Nervus Hypoglossus bei extremer Schlingenbildung der Arteria Carotis Interna. *Neurochirurgia* 1974;17:91-95
4. Scotti G, Melançon D, Oliver A. Hypoglossal paralysis due to compression by a tortuous internal carotid artery in the neck. *Neuroradiology* 1978;14:263-265
5. Ueda S, Kohyama Y, Takase K. Peripheral hypoglossal nerve palsy caused by lateral position of the external carotid artery and an abnormally high position of bifurcation of the external and internal carotid arteries—a case report. *Stroke* 1984;15(4):736-739
6. Hommel M, Pollak P, Gaio JM, Pellert J, Perret J, Chateau R. Paralysis du nerf grand hypoglosse par deux anévrysmes et un anévrysme disséquant de l'artère carotide interne. *Rev Neurol (Paris)* 1984;140(6-7):415-421
7. Havelius U, Hindfelt B, Brismar J, Cronqvist S. Carotid fibromuscular dysplasia and paresis of lower cranial nerves (Collet-Sicard syndrome)—case report. *J Neurosurg* 1982;56:850-853
8. Farrell FW, Ellenberger C. Transient hemilingual paralysis. Selective compression of the twelfth nerve and jugular bulb by a saccular carotid aneurysm. *Neurology* 1972;22:1061-1064
9. Lane RJ, Weisman RA, Savino PJ, Schatz NJ. Aneurysm of the internal carotid artery at the base of the skull: an unusual cause of cranial neuropathies. *Otolaryngol Head Neck Surg* 1980;88:230-232
10. Nathan H, Levy J. The course and relations of the hypoglossal nerve and the occipital artery. *Am J Otolaryngol* 1982;3(2):128-132