AJNR

Effect of bromocriptine and pergolide on pituitary tumor size and serum prolactin.

B L Horowitz, D J Hamilton, C J Sommers, R N Bryan and A E Boyd, 3rd

AJNR Am J Neuroradiol 1983, 4 (3) 415-417
http://www.ajnr.org/content/4/3/415

Effect of Bromocriptine and Pergolide on Pituitary Tumor Size and Serum Prolactin

Barry L. Horowitz,[1] Dale J. Hamilton,[2] Cynda J. Sommers,[2] R. Nick Bryan,[1] and Aubrey E. Boyd III[2]

Forty-two patients with elevated serum prolactin were treated in a randomized, open-label trial with the conventional ergot bromocriptine, or a new ergot pergolide. Before treatment, the patients underwent thorough endocrine evaluation and computed tomographic scan. All patients had prolactin levels greater than 25 ng/ml, and 27 patients had a pituitary mass. Follow-up studies performed after 6 months of treatment showed both drugs effectively reduced prolactin levels to normal, though pergolide effects were more rapid. There was no change in the contents of the pituitary fossa in the 10 patients with hyperprolactinemia but without pituitary mass. Sixty percent of patients with pituitary mass had diminution of tumor size. Pergolide appears to be an effective medical treatment for hyperprolactinemia and pituitary tumor and offers a possible alternative to bromocriptine and surgical treatment.

Prolactin-secreting pituitary adenomas have been successfully treated surgically and with the ergot derivative bromocriptine [1–7]. Medical management is increasingly popular because of its effective correction of elevated serum prolactin levels as well as the associated clinical syndrome of amenorrhea and galactorrhea. Recently, bromocriptine has been shown to shrink the size of prolactinomas [8–10].

Pergolide, a new long-acting ergot derivative, has been reported to be more potent than bromocriptine by weight and have a longer duration of action (>24 hr) [11, 12]. We evaluated the effectiveness of pergolide and bromocriptine in the management of patients with the hyperprolactinemia syndrome. Of particular interest was the ability of the drugs to return prolactin levels to normal and to decrease the size of tumors on follow-up computed tomographic (CT) scans.

Subjects and Methods

Forty-two patients with hyperprolactinemia (27 women and 15 men) were initially evaluated by endocrine studies and CT. A definite diagnosis of pituitary tumor was made in 34 patients and confirmed by previous surgery in 27 patients. The other patients with a "definite" diagnosis of pituitary adenoma had elevated serum prolactin concentrations (>25 ng/ml) and an abnormal high-resolution CT scan. Ten patients had elevated serum prolactin levels and the appropriate clinical syndrome, but did not have a definitely abnormal CT scan. Two of these patients had previous surgery but the residual tumor could not be identified on the postoperative CT scan. Patients with previously operated adenomas, nonoperated "definite" pituitary adenomas, and hyperprolactinemic patients with normal CT scans were evenly distributed between the bromocriptine and pergolide treatment groups. Their ages were 21–67 years.

All patients were admitted to the Clinical Research Center at Baylor College of Medicine. Complete medical histories were recorded and physical examinations given. In addition to preliminary CT scans, routine laboratory analysis and assessment of pituitary, thyroid, adrenal, and gonadal functions were performed. All CT scans consisted of 2-mm-thick, contiguous coronal sections through the pituitary fossa after a bolus intravenous injection of 50 ml of 80% sodium-meglumine iothalamate, followed by a rapid continuous drip during scanning.

The radiologic diagnosis of pituitary macroadenoma was based on CT demonstration of an obvious mass greater than 1 cm in diameter. The radiographic diagnosis of microadenoma related to lesions less than 1 cm in diameter [13]. The criteria for the diagnosis of microadenoma included an upward convexity of the diaphragma; discrete, focal radiolucency within the pituitary gland; lateral deviation of the pituitary stalk; and erosion of the floor of the pituitary fossa with soft tissue protruding into the sphenoid sinus. A secondary sign was asymmetry of the pituitary fossa with a horizontal sloping of the floor greater than 30°.

Patients were assigned to either the bromocriptine or the pergolide treatment group by a computer-generated randomized sequence using an open label protocol. Patients assigned to the bromocriptine protocol received 5–10 mg/day, divided into two or three oral doses. Patients assigned to the pergolide protocol received single daily doses of 50–100 μg, except one patient with acromegaly and a tumor-secreting mixed prolactin and growth hormone who received 350 μg.

Serum prolactin levels were measured hourly for a 24 hr period during the initial hospitalization, at monthly intervals for the first 6 months, and then at 2–3 month intervals. Follow-up CT scans were obtained at 6 month intervals.

Results

Forty-two patients were started on treatment with the protocol drugs for a period of up to 2 years. Three patients were unable to complete the protocol due to side effects (nausea and vomiting).

[1] Department of Radiology, Baylor College of Medicine, Houston, TX 77030.
[2] Department of Medicine, Baylor College of Medicine, Houston, TX 77030. Address reprint requests to R. Nick Bryan, Department of Radiology, Mail Station NB703, Methodist Hospital, 6565 Fannin, Houston, TX 77030.

AJNR 4:415–417, May/June 1983 0195-6108/83/0403-0415 $00.00

This group included one patient on pergolide and two patients on bromocriptine. Five patients became pregnant (three pergolide, two bromocriptine), and four delivered normal infants. Only one of these patients had a 6 month CT scan prior to pregnancy. In one patient, extreme obesity prevented CT scanning, and patient artifacts made CT scans difficult to interpret in another. Thus, 33 patients had a 6 month protocol follow-up including a CT scan. There were no significant differences in adverse side effects in the patients chronically treated with either drug.

In 17 patients (95%) treated with pergolide and in 15 patients (88%) treated with bromocriptine, prolactin levels returned to normal. In the pergolide group, serum prolactin levels before treatment were 44.2–398 ng/ml (average, 136.3 ng/ml). After treatment, serum prolactin levels were <1.0–48.9 ng/ml (average, 7 ng/ml). Serum prolactin levels before treatment in the patients on the bromocriptine protocol were 41–1,850 ng/ml (average, 268.1 ng/ml). After treatment, levels were <1.0–124 ng/ml (average, 36 ng/ml). There was no statistically significant difference between the two groups in terms of pre- or posttreatment prolactin levels.

All six patients with macroadenomas treated with pergolide showed dimunition in tumor size (fig. 1), as did three of six treated with bromocriptine. No tumors in either group increased in size during the follow-up period. Of the six patients with microadenomas treated with pergolide two tumors showed diminution in size (fig. 2), as did three tumors in five patients with microadenomas treated with bromocriptine (fig. 3). There were no significant changes in the CT scans of the 10 patients who did not have CT evidence of pituitary tumor before treatment.

Discussion

Pergolide is a potent dopamine agonist capable of suppressing serum prolactin concentration for more than 24 hr in hyperprolactinemic patients. This confirms an earlier report by Franks et al. [14] indicating that this drug need be given only once daily, a considerable advantage over bromocriptine, which must be administered two or three times daily. On a dosage basis, pergolide is also a more potent drug, requiring less than 100 μg daily to return 90% of elevated prolactin levels to normal, while bromocriptine requires 5–10 mg for similar results. This is an approximate potency ratio of 100:1. This greater therapeutic potency is not associated with increased side effects.

As demonstrated by CT, neither of the drugs was associated with the bulk growth of pituitary tumors. Of 11 patients who had CT evidence of pituitary microadenomas, five showed diminution in size of the lesions. These results and those of others [15, 16] would suggest that medical treatment of some of these lesions may in fact restore normal sexual function and control the growth of the tumor. However, it must be noted that the follow-up period in this study is relatively brief (6 months–2 years) and the patients will have to be followed closely, including CT, until more data are obtained indicating the permanency of the therapeutic results. It is also unclear how long it takes to shrink these lesions, although responses have been reported as early as 2 days to a few weeks after treatment [10, 14]. Shrinkage was noted as early as 1 month in our study.

Diminution of macroadenoma size occurred in nine of 12 patients, all of whom had failed surgical treatment and two of whom had also failed radiotherapy. These results suggest that medical management of these lesions may obviate reoperation. It must be remembered that this particular population in our study is skewed by a large number of the patients having had previous unsuccessful surgery. In such patients it may be difficult to determine if there are small decreases in the residual tumor because the sella is usually filled with spinal fluid. This makes it hard to distinguish the tumor from the remaining pituitary or postoperative scar tissue. Again, it will be important to follow these patients closely for a much longer period of time to determine the efficacy of chronic treatment, because a few reports have shown a definite increase in macroadenoma size after being treated with bromocriptine. The role of radiotherapy in these lesions remains unclear.



A B

Fig. 1.—Pre- (**A**) and post- (**B**) pergolide treatment of pituitary macroadenoma after contrast enhancement in patient with previous unsuccessful surgery. Tumor size is markedly diminished in **B**, showing pituitary neoplastic tissue restricted to pituitary fossa.

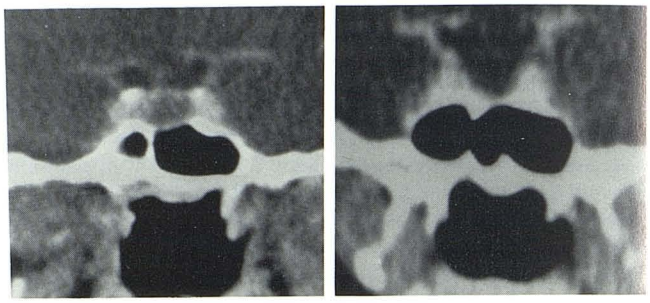

A B

Fig. 2.—Pre- (**A**) and post- (**B**) pergolide treatment of nonoperated amenorrhea galactorrhea syndrome patient. **A**, Evidence of pituitary microadenoma with upper convexity of the diaphragma and lucent pituitary fossa contents. **B**, Tumor size is markedly diminished with predominantly "empty" sella.

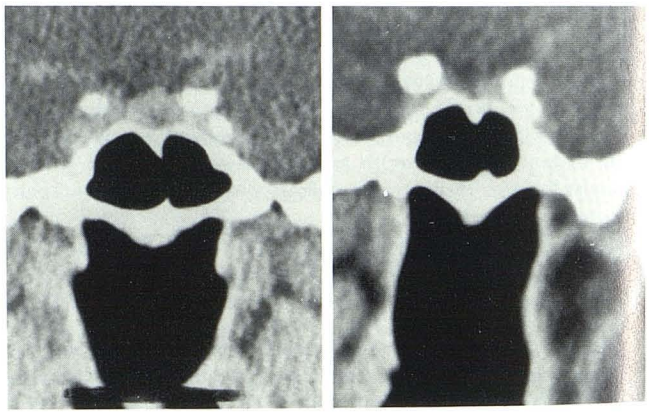

A B

Fig. 3.—Pre- (**A**) and post- (**B**) bromocriptine treatment of pituitary microadenoma in patient with amenorrhea galactorrhea. **A**, Small upward bulging of pituitary gland and diaphragma with slight radiolucency of tumor region. **B**, Pituitary fossa contents are diminished with partly empty sella.

We believe that pergolide has been shown to be equally or more effective than bromocriptine in the medical management of hyperprolactinemia syndromes. It also offers the advantages of single daily dosage and greater potency. The precise role of the ergots in the management of patients with prolactinomas remains to be defined. It is clear that most large tumors will diminish on medical therapy. Whether the drugs can be used as a primary therapy of macroadenomas or whether tumor shrinkage facilitates a subsequent surgical removal is not yet established. In patients with residual tumor after surgery, medical treatment has normalized prolactin levels and prevented detectable tumor growth by CT for up to 2 years. Drug therapy in these patients may be more selective than radiotherapy. In patients with microadenomas, where the chances of a complete surgical removal and possible cure are high, the use of ergot therapy as a primary mode of treatment requires further study.

REFERENCES

1. Besser GM, Parke L, Edwards CRW, Forsyth IA, McNeilly AS. Galactorrhoea: successful treatment with reduction of plasma prolactin levels by brom-ergocryptine. *Br Med J* **1972**;3:669–672
2. Besser GM, Thorner MO. Session III. Recent clinical evidence with bromocriptine. Bromocriptine in the treatment of the hyperprolactinaemia-hypogonadism syndromes. *Postgrad Med J* **1976**;52(suppl 1):64–70
3. Friesen HG, Tolis G. The use of bromocriptine in the galactorrhoea-amenorrhoea syndromes: the Canadian Cooperative Study. *Clin Endocrinol* (Oxf) **1977**;6:91s–99s
4. Liuzzi A, Chiodini PG, Oppiggi G, et al. Lissuride hydrogen maleate: evidence for a long lasting dopaminergic activity in humans. *J Clin Endocrinol Metab* **1978**;46:196
5. DelPozo E, Brun Del Re R, Varga L, Friesen H. The inhibition of prolactin secretion in man by CB-154. *J Clin Endocrinol Metab* **1972**;35:768–771
6. Kleinberg DL, Noel GL, Frantz AG. Galactorrhea: a study of 235 cases, including 48 with pituitary tumors. *N Engl J Med* **1977**;296:589–600
7. Boyd AE III, Reichlin S, Turksoy RN. Galactorrhea-amenorrhea syndrome: diagnosis and therapy. *Ann Intern Med* **1977**;87:165–175
8. Coreblum B, Webster BR, Mortimer CS, Ezrin C. Possible antitumor effect of 2 bromo-ergocryptine (CB-154 Sandoz) in 2 patients with large prolactin secreting pituitary adenomas. *Clin Res* **1975**;23:614A
9. McGregor AM, Scanlon MF, Hall K, Cook DB, Hall R. Reduction in size of a pituitary tumor by bromocriptine therapy. *N Engl J Med* **1979**;300:291–293
10. George SR, Burrow GN, Zinman B, Ezrin C. Regression of pituitary tumors, a possible effect of bromergocryptine. *Am J Med* **1979**;66:697–702
11. Lemerger L, Crabtree RE. Pharmacologic effects in man of a potent long-acting dopamine receptor agonist. *Science* **1979**;205:1151
12. Kleinberg DL, Lieberman A, Todd J, Greising J, Neophytides A, Kupersmith M. Pergolide mesylate: a potent day-long inhibitor of prolactin in rhesus monkeys and patients with Parkinson's disease. *J Clin Endocrinol Metab* **1980**;51:152–154
13. Syvertsen A, Haughton V, Williams A, Cusick J. Computed tomographic appearance of the normal pituitary gland and pituitary microadenomas. *Radiology* **1979**;133:385
14. Franks S, Horrocks PM, Lynch SS, Butt WR, London DR. Treatment of hyperprolactinaemia with pergolide mesylate: acute effects and preliminary evaluation of long-term treatment. *Lancet* **1981**;2:659–661
15. Wass JAH, Williams J, Charlesworth M, et al. Bromocriptine in the management of large pituitary tumors. *Br Med J* (in press)
16. Spark RF, Baker R, Beinfang DC, Bergland R. Bromocriptine reduces pituitary tumor size and hypersecretion. Requiem for pituitary surgery? *JAMA* **1982**;247:311–316