

A growing portfolio of cost-effective  
CT and MRI **Generic Contrast Agents.**

Now you have a choice. RSNA 2024 | Booth #3235

DISCOVER MORE



**AJNR**

## **Radiation-Induced Cavernomas of the Brain**

Rajan Jain, Patricia L. Robertson, Dheeraj Gandhi, Sachin K. Gujar, Karin M. Muraszko and Stephen Gebarski

*AJNR Am J Neuroradiol* 2005, 26 (5) 1158-1162

<http://www.ajnr.org/content/26/5/1158>

This information is current as  
of November 16, 2024.

## Case Report

# Radiation-Induced Cavernomas of the Brain

Rajan Jain, Patricia L. Robertson, Dheeraj Gandhi, Sachin K. Gujar,  
Karin M. Muraszko, and Stephen Gebarski

**Summary:** The purpose of this report is to add support to the growing literature that there is a correlation between radiation and cavernomas of the brain, particularly if the radiation is received in childhood, as well as to increase awareness of this correlation in the radiology community. Retrospective review of our experience returned five patients who received radiation therapy while they were children and developed cavernomas in the irradiated tissues 3–41 years later. Cavernomas should be considered in the differential diagnosis of a hemorrhagic lesion in any patient who has received previous CNS radiation, particularly if he or she underwent radiation therapy in childhood.

Cavernomas—also known as cavernous hemangiomas and cavernous malformations—are CNS vascular lesions composed of thin-walled, dilated capillary spaces with no intervening brain tissue (1). Most cavernomas are believed to be of congenital origin, either sporadic or autosomal dominant with incomplete penetrance, and have an incidence as high as 0.5% (2). A correlation between radiation therapy and cavernoma has been suspected since 1994 (3). Since that time, additional cases have appeared in the literature (4–10), although only a few reports have been published in the radiology literature (7–9).

### *Findings in Our Five Patients*

Our institutional review board ruled that this research project was exempt from review.

Retrospective review of our experience with cavernomas over the past 3 years returned five patients who developed cavernomas in the treated field after having received prior cranial or craniospinal irradiation (Table). Age range at diagnosis of the cavernomas was 6–57 years (mean, 27 years). Age range at the time of irradiation was 3–16 years (mean, 7.5 years). Latency interval between the time of irradiation and time of detection of the cavernomas was 3–41 years (mean, 19.5 years). The mean latency period was 16 years for the patients irradiated in the 1st decade and 24.5 years for those irradiated in the 2nd decade. All cavernomas were in the irradiated field. Two patients received whole-brain irradiation for posterior fossa medulloblastomas (Fig 1), one received involved field irradiation for a posterior fossa ependymoma

(Fig 2), one received craniospinal radiation for a suprasellar germinoma (Fig 3), and the fifth patient received cobalt radiation therapy for Cushing disease.

Cavernomas were diagnosed incidentally in all five patients on routine surveillance imaging of their tumors or while being evaluated for unrelated problems. Two patients had multiple cavernomas, one with four lesions and the other with at least two lesions detected by use of MR imaging (Table). Progressive hemorrhage with enlargement of one cavernoma was seen on serial images in each of these two patients, although both were asymptomatic for bleeding. These cavernomas were in surgically accessible locations and were resected because of the progressive hemorrhage and in view of their increased risk for further bleeding. Histopathologic results confirmed the diagnosis of cavernoma. At the time of this writing four patients with seven lesions are being followed up with surveillance imaging.

Three patients also had other radiation-induced neoplasms, including two patients with meningiomas and one with a scalp juvenile dermatofibrosarcoma, all in the irradiated fields. Three patients also had hypothalamic-pituitary axis dysfunction related to radiation injury.

### Discussion

Many of the deleterious effects of radiation on the CNS are well known. These include early effects that can occur within a few weeks of the radiation therapy, such as vasogenic edema due to increased capillary permeability and vasodilation (10) and delayed effects that can occur months to years after the irradiation. The latter include cerebral atrophy, white matter necrosis, demyelination, gliosis, and induction of neoplasm (10).

Delayed radiation injury, however, can also manifest as vasculopathy with hyalinization and fibrinoid necrosis of vascular walls, resulting in occlusion and infarction as well as vascular proliferative lesions such as capillary telangiectasia and cavernoma (4, 11–13). Capillary telangiectasias, thin-walled ectatic capillaries with intervening normal brain parenchyma, which distinguishes them from cavernomas, usually occur 3–9 months after irradiation (12, 13). Cavernomas take a longer time to develop after radiation. Reported latency periods for radiation-induced cavernomas range from 1 to 26 years (4).

It is interesting to note that capillary telangiectasias and cavernomas may be sequential variations of the same pathologic process (5, 14). Cavernomas have been hypothesized to result from a proliferative vasculopathy that begins with the development of capillary telangiectasias triggered by radiation injury to the cerebral microcirculation (5). Increased expression of vascular endothelial growth factor (VEGF) has been demonstrated in an animal model of radiation-in-

Received February 25, 2004; accepted after revision July 30.

Presented at the 41st annual meeting of the American Society of Neuroradiology, Washington, D.C., April 26–May 2, 2003.

From the Departments of Radiology (R.J., D.G., S.K.G., S.G.), Neurology (P.L.R.), and Neurosurgery (K.M.M.), University of Michigan Medical School, Ann Arbor, MI.

Address correspondence to Rajan Jain, MD, Division of Neuro-radiology, Department of Radiology, Henry Ford Health System, 2799 West Grand Boulevard, Detroit, MI 48202.

## Case Material

Case No.	Age* / Sex	Primary CNS Neoplasm Or Disease	Age at RT (years)	RT and Dose	Latency Interval (years)	Clinical Presentation	Location of CM's	Number of CM's	Treatment of CM's	Associated Findings
1	18/F	Posterior fossa Medulloblastoma	3	Craniospinal RT 54 Gy (T) 36 Gy (CS)	15	Incidental	Lt temporal lobe/ Intraventricular	1	Observation	Meningioma Scalp DFS Panhypopituitarism
2	6/M	Posterior fossa Ependymoma	3	Involved field RT 50.4 Gy	3	Incidental (Subsequent asymptomatic Hemorrhage)	Rt cerebellum Lt cerebellum Rt cerebellum Rt temporal lobe	1 1 2 1	Observation Surgery Observation Observation	TH & GH Deficiency
3	34/M	Posterior fossa Medulloblastoma	3	Craniospinal RT 54 Gy (T) 36 Gy (CS)	31	Incidental	Lt frontal lobe	1	Observation	Meningioma
4	21/M	Supra-sellar Germinoma	13	Craniospinal RT 50.4 Gy (T) 36 Gy (CS)	8	Incidental (Subsequent asymptomatic hemorrhage)	Rt fronto-parietal lobe	1	Surgery	-
5	57/F	Cushing's Disease	16	Cobalt RT Unknown dose	41	Incidental	Rt frontal lobe	1	Observation	Panhypopituitarism

Note.—Age\* indicates Age at the time of diagnosis of cavernomas; RT, Radiation therapy; T, Total Dose; CS, Craniospinal Dose; CM's, cavernous malformations; DFS, Dermatofibrosarcoma; TH, Thyroid hormones; GH, Growth hormone.

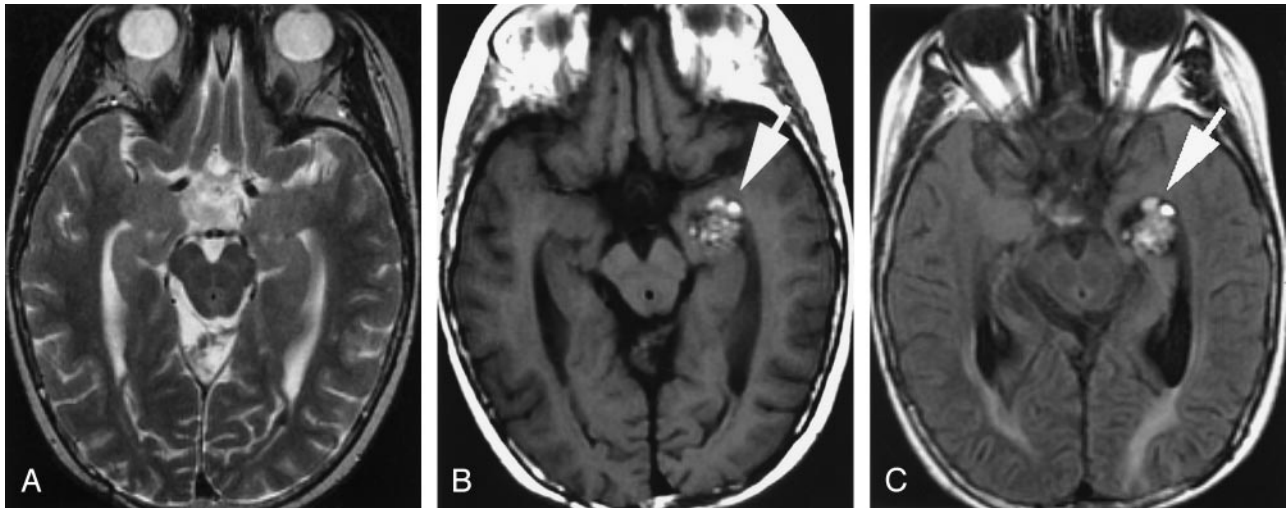


FIG 1. Case 1.

A, Axial T2-weighted MR image obtained 12 years after craniospinal radiation therapy at 3 years of age for a posterior fossa medulloblastoma showing no lesion in the left temporal lobe/temporal horn.

B, Axial T1-weighted and, C, fluid-attenuated inversion recovery (FLAIR) MR images obtained 15 years after the radiation therapy, showing a lobulated area of mixed signal intensity with peripheral hypointense rim (*white arrow*) in left medial temporal lobe/temporal horn, typical "popcorn" MR appearance of a cavernous angioma.

duced spinal injury. VEGF, along with other possible vasculogenic factors, could initiate such neoangiogenesis, inducing the formation of capillary telangiectasia that eventually develops into cavernomas (15). An alternative explanation is that radiation may cause direct DNA damage, which leads to formation of cavernomas. DNA mutations at multiple foci have been linked to the autosomal dominant form of cavernoma development (3, 16).

Ciricillo et al (3) first reported cavernomas as a possible result of prior CNS irradiation in 1994. Gaensler et al (8) described the appearance of hemorrhagic foci on MR images following CNS irradiation; these foci were similar to the cryptic vascular malformations described as radiation-induced telangiectasia. Koike et al (9) concluded that radiation-induced telangiectasia appeared to occur in at least 20% of children who undergo cranial irradiation; however, higher radiation dose was not significantly associated with higher frequency of telangiectasia, although there was a trend in this direction. From one of the recent analysis of 40 patients reported in the literature through 2002, a conclusion was made that, not only are cavernomas induced by radiation, but also that this occurs at a significantly higher rate when patients are irradiated as children (4). In that study, a significant preponderance of cavernomas was found in patients who were irradiated as children, even when the analysis was controlled for possible selection bias of their potentially longer survival times and the relatively high incidence of sporadic and familial cavernoma. Our series, in which all five patients were children at the time they received radiation therapy, supports this conclusion. A possible explanation for this relationship is that some of the angiogenic factors hypothesized to be involved in the development of cavernomas after irradiation are expressed at the highest levels in children (17, 18).

Analysis of previously reported radiation-associated cavernomas found a correlation between a radiation dose  $>30$  Gy and a shorter latency to development of cavernomas (4). This could not be assessed in our series because all four patients for whom the radiation dose was known received a total dose  $>30$  Gy to the field in which the cavernoma was found. We found a mean latency of 16 years for our patients, who received radiation when they were  $<10$  years old. This is significantly longer than the 4.75-year mean latency reported in the literature for such patients (4). The reason for this difference is not certain but could reflect that all of our patients were asymptomatic from their cavernomas. Accordingly, the cavernomas in our patients may have been present long before they were detected. Our finding of 100% asymptomatic patients matches one of the most recent studies about asymptomatic radiation-induced telangiectasias (9) although in another study 50% of the 40 reported patients had signs or symptoms referable to their cavernomas (4). Two of our five patients showed recent asymptomatic hemorrhage associated with their cavernomas. Cavernomas are associated with hemorrhage, but the estimated risk is only 0.25–0.7% per year (19, 20). Radiation-induced cavernomas may, however, have increased risk of hemorrhage (5).

The appearance of a new brain lesion or hemorrhage in a patient who has undergone radiation therapy for a CNS neoplasm always raises the possibility of neoplastic recurrence or metastases. Ordinarily, it is not difficult to differentiate a cavernoma from other neoplasms, because most cavernomas have a distinctive appearance of their nidus with little or no surrounding edema. Acute hemorrhage can complicate the appearance and result in blurring of the nidus and reactive edema, but differentiation is still usually possible on the basis of the CT and MR imaging character of the nidus (6). MR imaging usu-

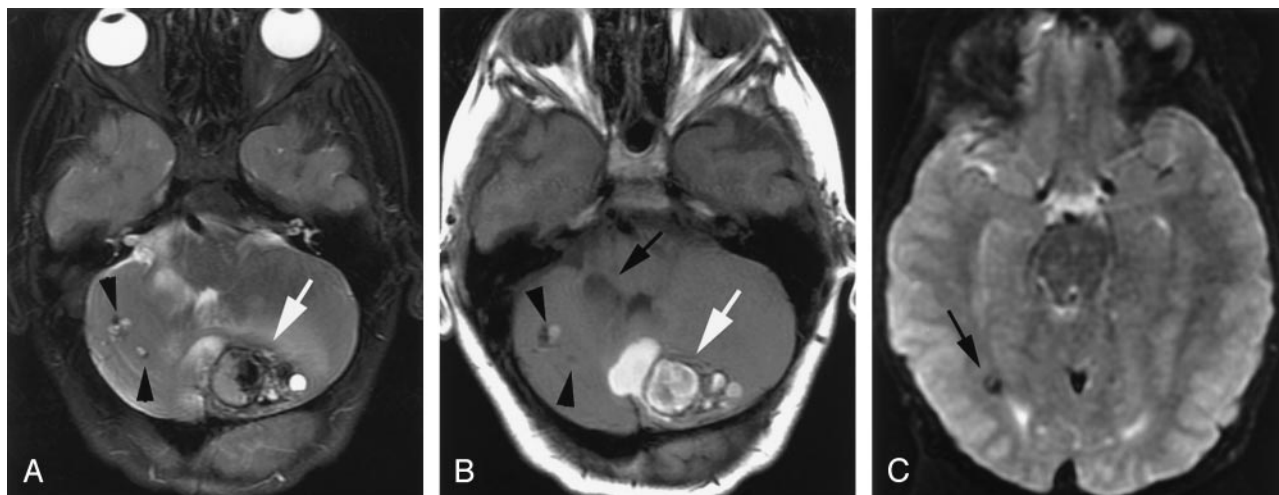


FIG 2. Case 2.

A, Axial T2- and, B, T1-weighted MR images obtained 3 years after involved field radiation therapy at 3 years of age for a posterior fossa ependymoma showing a large hemorrhagic, lobulated lesion of mixed signal intensity (*white arrow*) in left cerebellar hemisphere and vermis. Two more small cavernomas (*black arrowheads*) are seen in the right cerebellum. Postoperative changes (*black arrow*) are noted in the right cerebellum.

C, Axial T2\*-weighted MR image shows an area of blooming due to another small cavernoma (*black arrow*) in the right temporo-occipital region.

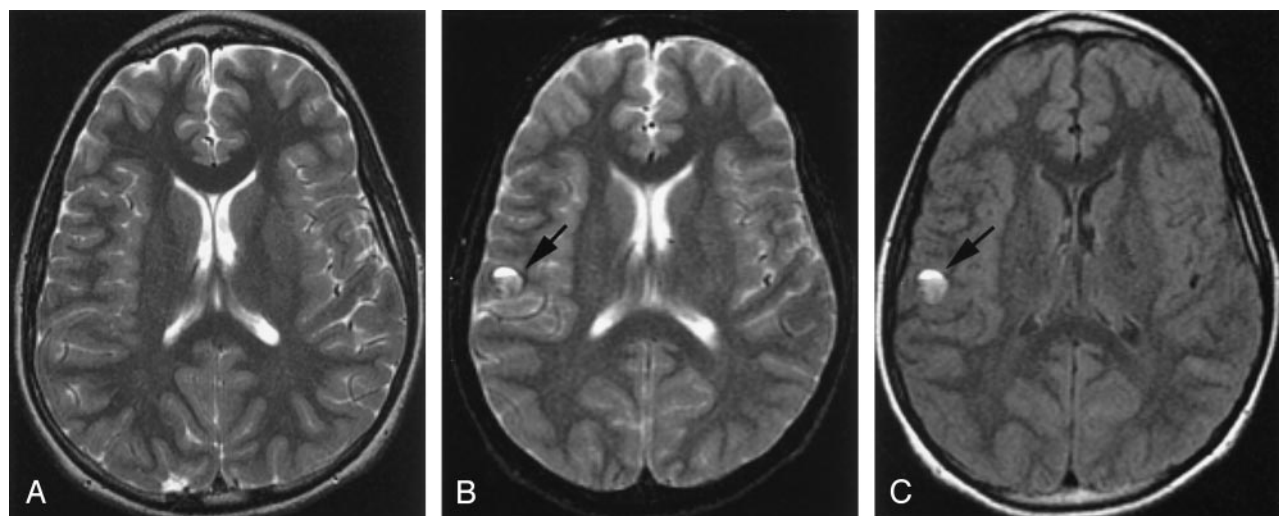


FIG 3. Case 4.

A, Axial T2-weighted MR image obtained 6 years after craniospinal radiation therapy at age 13 years for a suprasellar germinoma showing no lesion in right frontoparietal region.

B, Axial T2-weighted and, C, FLAIR MR images obtained 8 years after the radiation therapy showing interval appearance a round lesion of mixed signal intensity with a fluid-fluid level and peripheral hypointense rim (*black arrow*) in right frontoparietal region.

ally shows a reticulated core of heterogeneous signal intensity with a dark peripheral rim of hemosiderin, giving a typical “popcorn” appearance (14). CT usually shows ring-like calcification with core reticulation of variable attenuation.

### Conclusion

In light of the fairly well established correlation between radiation and cavernoma formation, it is prudent to consider cavernoma in the differential diagnosis of a hemorrhagic lesion in any patient who has received previous CNS radiation, particularly if he or she underwent radiation therapy in childhood.

### References

1. Russel DS, Rubinstein LJ. *Pathology of Tumors of the Nervous System*. 5th ed. Baltimore: Williams and Wilkins;1989:730–736
2. Rigamonti D, Hadley MN, Drayer BP, et al. **Cerebral cavernous malformations: incidence and familial occurrence**. *N Engl J Med* 1988;319:343–347
3. Ciricillo SF, Cogen PH, Edwards MS. **Pediatric cryptic vascular malformations: presentation, diagnosis and treatment**. *Pediatr Neurosurg* 1994;20:137–147
4. Heckl S, Aschoff A, Kunze S. **Radiation-induced cavernous hemangiomas of the brain: a late effect predominantly in children**. *Cancer* 2002;94:3285–3291
5. Larson JJ, Ball WS, Bove KE, et al. **Formation of intracerebral cavernous malformations after radiation treatment for central nervous system neoplasia in children**. *J Neurosurg* 1998;88:51–56
6. Olivero WC, Deshmukh P, Gujrati M. **Radiation-induced cavern-**

- ous angioma mimicking metastatic disease. *Br J Neurosurg* 2000;14:575-578
7. Maeder P, Gudinchet F, Meuli R, et al. **Development of a cavernous malformation of the brain.** *Am J Neuroradiol* 1998;19:1141-1143
  8. Gaensler EH, Dillon WP, Edwards MS, et al. **Radiation-induced telangiectasia in the brain simulates cryptic vascular malformations at MR imaging.** *Radiology* 1994;193:629-636
  9. Koike S, Aida N, Hata M, et al. **Asymptomatic radiation-induced telangiectasia in children after cranial irradiation: frequency, latency, and dose relation.** *Radiology* 2004;230:93-99 [Epub November 26, 2003]
  10. Valk PE, Dillon WP. **Radiation injury of the brain.** *AJNR Am J Neuroradiol* 1991;12:45-62
  11. Poussaint TY, Siffert J, Barnes PD, et al. **Hemorrhagic vasculopathy after treatment of central nervous system neoplasia in childhood: diagnosis and follow-up.** *AJNR Am J Neuroradiol* 1995;16:693-699
  12. Hassler O, Movin A. **Microangiographic studies on changes in the cerebral vessels after irradiation. I. Lesions in the rabbit produced by 60Co gamma-rays, 195kV and 34MV roentgen rays.** *Acta Radiol Ther Phys Biol* 1966;4:279-288
  13. Reinhold HS, Hopewell JW. **Late changes in the architecture of blood vessels of the rat brain after irradiation.** *Br J Radiol* 1980;53:693-696
  14. Rigamonti D, Drayer BP, Johnson PC, et al. **The MRI appearance of cavernous malformations (angiomas).** *J Neurosurg* 1987;67:518-524
  15. Tsao MN, Li YQ, Lu G, et al. **Upregulation of vascular endothelial growth factor is associated with radiation-induced blood-spinal cord barrier breakdown.** *J Neuropathol Exp Neurol* 1999;58:1051-1060
  16. Gunel M, Awad IA, Finberg K, et al. **Genetic heterogeneity of inherited cerebral cavernous malformation.** *Neurosurgery* 1996;38:1265-1271
  17. Rivard A, Berthou-Soulie L, Principe N, et al. **Age-dependent defect in vascular endothelial growth-factor expression is associated with reduced hypoxia-inducible factor 1 activity.** *J Biol Chem* 2000;275:29643-29647
  18. Malamitsi-Puchner A, Tziotis J, Tsonou A, et al. **Changes in serum levels of vascular endothelial growth factor in males and females throughout life.** *J Soc Gynecol Investig* 2000;7:309-312
  19. Del Curling O Jr, Kelly DL Jr, Elster AD, Craven TE. **An analysis of the natural history of cavernous angiomas.** *J Neurosurg* 1991;75:702-708
  20. Robinson JR, Awad IA, Little JR. **Natural history of the cavernous angioma.** *J Neurosurg* 1991;75:709-714