

The **next generation** GBCA
from Guerbet is here

Explore new possibilities >

Guerbet | 

© Guerbet 2024 GUOB220151-A

AJNR

Development of aneurysm from infundibulum of posterior communicating artery with documentation of prior hemorrhage.

S Trasi, L M Vincent and L H Zingesser

AJNR Am J Neuroradiol 1981, 2 (4) 368-370
<http://www.ajnr.org/content/2/4/368.citation>

This information is current as
of July 2, 2024.

Development of Aneurysm from Infundibulum of Posterior Communicating Artery with Documentation of Prior Hemorrhage

Sunil Trasi,¹ Lawrence M. Vincent, and
Lawrence H. Zingesser

The clinical significance of infundibular widening (junctional dilatation) of the origin of an intracranial artery has been a topic of debate; junctional dilatation is considered preaneurysmal by some investigators and a normal variant by others. Aneurysm formation or hemorrhage from an infundibulum rarely has been reported. A patient is reported in whom both aneurysm development at the infundibulum and bleeding from this site are documented. This experience suggests the possible value of repeat delayed angiography when only junctional dilatation is identified in the face of unexplained subarachnoid hemorrhage.

Case Report

A 26-year-old woman, 6 months pregnant with no significant medical history, was discovered unconscious and brought to the emergency room. She regained consciousness, but was confused and lethargic, vomiting, and complaining of a severe headache. Physical examination revealed neck stiffness without focal neurologic deficits. Skull radiographs and CT scans were negative; spinal tap was grossly bloody.

Four-vessel angiography with magnification and subtraction techniques, performed later that day, revealed no evidence for aneurysm, arteriovenous malformation, or vascular spasm. There was junctional dilatation at the origin of both posterior communicating arteries (fig. 1A). She was given aminocaproic acid (Amicar) for 1 week, treated symptomatically with analgesics, and discharged 27 days after admission.

After an uncomplicated term pregnancy and cesarian delivery, the patient was readmitted for angiographic reevaluation. She was asymptomatic, and neurologic examination was unremarkable. Repeat four-vessel angiography demonstrated a widened infundibulum on the left, with a small aneurysm arising eccentrically at the origin of the posterior communicating artery (fig. 1B).

Elective left pterional craniotomy for clipping of the aneurysm was performed 3 weeks after admission. The aneurysm was broad-based and appeared not unlike a widened infundibulum, though eccentrically located (fig. 2). Evidence of prior bleeding included a large amount of adhesions in the area, with the left oculomotor nerve densely adherent to the dome of the aneurysm. The aneurysm

was successfully clipped, and the postoperative course was uneventful.

Discussion

An infundibulum or junctional dilatation is a commonly observed funnel-shaped outpouching at the origin of the posterior communicating artery. According to Taveras and Wood [1] "the dilatation should be considered as a possible aneurysm only when it measures more than 3 mm in diameter or when the posterior communicating artery does not join the dilatation at its apex."

Histologic reports concerning this entity are conflicting. Hassler and Saltzman [2], finding media defects and occasional defects in the internal elastic membranes of widened infundibula, suggested that these appearances are identical with those of a minute aneurysm. Epstein et al. [3], on the other hand, finding normal vascular morphology in their series of autopsy specimens, concluded that junctional dilatation is a normal variation, and not a site having predilection to bleeding or future true aneurysmal dilatation.

Nonetheless, subsequent case reports have demonstrated aneurysms of the posterior communicating artery developing at the site of infundibular widening without rupture [4–6], and there is a recent documentation of a ruptured infundibulum at autopsy [7]. In our patient, repeat panangiography almost 6 months after the initial bleeding demonstrated the interval appearance of an aneurysm, which was documented at surgery as a site of prior hemorrhage. Thus, this case lends support to the view that infundibular widening may be preaneurysmal, and illustrates the potential value of repeat angiography under these circumstances.

The incidence of normal arteriography in patients with subarachnoid hemorrhage has been reported fairly frequently in the literature. West et al. [8] reported normal cerebral arteriography in only 7% of 220 patients with subarachnoid hemorrhage, comparing these results with the significantly higher percentages in older reviews [18%–

Received September 29, 1980; accepted after revision January 29, 1981.

¹All authors: Department of Radiology, St. Vincent's Hospital, 153 W. 11th St., New York, NY 10011. Address reprint requests to S. Trasi.

Fig. 1.—**A**, Initial angiographic evaluation, left internal carotid injection. Infundibular widening (2.4 mm), accounting for magnification. No demonstrable aneurysm. Reflux into tip of basilar artery (b). **B**, Follow-up arteriogram 6 months later. Small aneurysm arises eccentrically at origin of left posterior communicating artery (arrow).

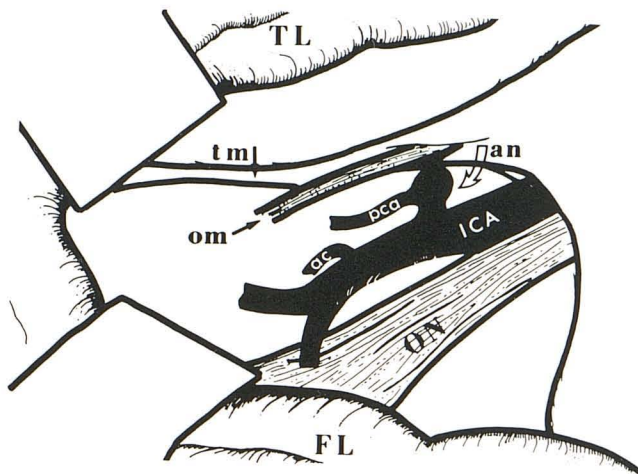
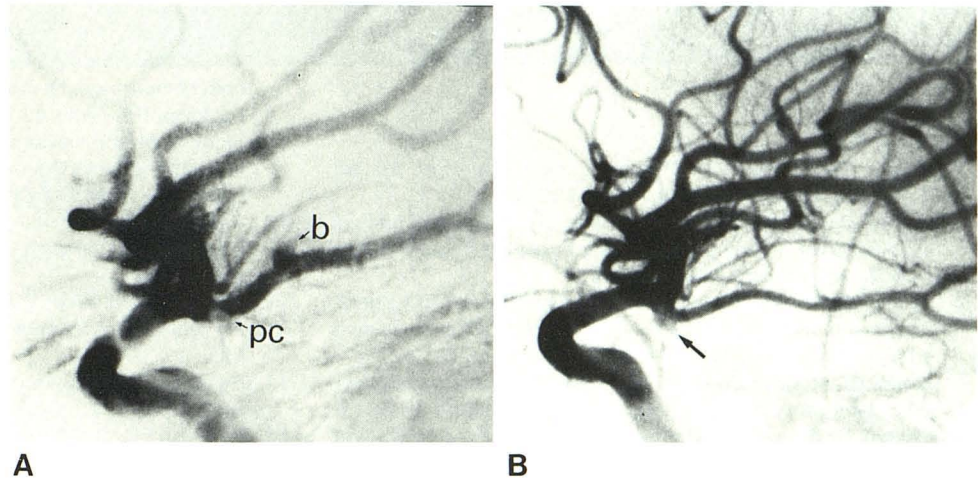


Fig. 2.—Representation of surgical findings: TL = temporal lobe; FL = frontal lobe; ON = optic nerve; tm = tentorial margin; om = oculomotor nerve; ICA = internal carotid artery; an = aneurysm; pca = posterior communicating artery; ac = anterior choroidal artery.

27%] and suggesting this decrease is principally due to technical improvements. Repeat angiography was performed on all normals in their study, but no mention was made of the percentage of initial false negatives. Abnormal cerebral arteriography would not be expected in instances of spinal arteriovenous malformation or tumor, rupture of a small superficial vessel, or other causes of subarachnoid hemorrhage [9]. Nonetheless, the greatest single cause of subarachnoid hemorrhage is rupture of aneurysm; the percentage of aneurysms in primary subarachnoid hemorrhage averaged 69% in one review [10].

Perret and Bull [11], correlating angiographic with autopsy findings, reported an 89% accuracy in the radiologic diagnosis of aneurysm, with a potential accuracy of 96% (assuming minimizing of observer error and obtainment of adequate projections). In their series, only 2% of patients with intracranial aneurysms had normal arteriography when reviewed. Aside from observer error, inadequate technique, and arterial spasm, explanations to account for nonvisuali-

zation of aneurysms by arteriography include thrombosis [12] and self-destruction of small aneurysms at time of rupture [13].

Forster et al. [14] dealt directly with the value of repeat angiography, reporting a false-negative rate of less than 2% in a series of 56 patients, and suggested that repeat studies are seldom justified unless further bleeding episodes occur. The mean interval between the subarachnoid hemorrhage and the second angiographic study was 30 days. In their preliminary series of 529 patients with subarachnoid hemorrhage, initial panangiography was negative in 28%. Of the group selected for repeat evaluation, six of the 56 had widened infundibula, but no conclusions could be drawn about their significance.

To date, there is no accepted doctrine for further evaluation of unexplained subarachnoid hemorrhage by repeat angiography. Yet when this situation is encountered, angiography may reveal only infundibular widening. Generally in such instances, no serious consideration is given to surgical intervention, but for the neuroradiologist pressed for a definitive interpretation, the conflicting histologic reports do not ease his discomfort, and the 3 mm size criterion seems arbitrary and of little practical value. Our case illustrates that delayed repeat angiography, independent of rebleeding, may be warranted under these conditions, particularly in the young healthy patient with a long life expectancy.

The use of the term "delayed" is intentional; we wish to emphasize the interval of nearly 6 months between initial and repeat studies in this report. In previous reports of aneurysm development at the site of a widened infundibulum (without rupture), years elapsed in all instances before this development was documented angiographically [4-6].

In regard to the more general issue of repeat angiography in cases of unexplained subarachnoid hemorrhage, we await further long-range studies. Repeat angiography may prove advisable in the younger age group. For patients suffering a subarachnoid hemorrhage from aneurysm and surviving 6 months, rebleeding occurs on the average of 3.5% per year during the first decade, with a 67% mortality associated with a late rebleed [15].

ACKNOWLEDGMENTS

We thank Mary McLarnon and Raj Murali for assistance.

REFERENCES

1. Taveras JM, Wood EH. *Diagnostic neuroradiology*, 2d ed. Baltimore: Williams & Wilkins, **1976**:585
2. Hassler O, Saltzman GF. Angiographic and histologic changes in infundibular widening of the posterior communicating artery. *Acta Radiol (Stockh)* **1963**;321-327
3. Epstein F, Ransohoff J, Budzilovich GN. The clinical significance of junctional dilatation of the posterior communicating artery. *J. Neurosurg* **1970**;33:529-531.
4. Stuntz JT, Ojemann GA, Alvord EC. Radiographic and histologic demonstration of an aneurysm developing on the infundibulum of the posterior communicating artery. *J Neurosurg* **1970**;33:591-595
5. Yoshimoto T, Suzuki J. Surgical treatment of an aneurysm on the funnel-shaped bulge of the posterior communicating artery. *J Neurosurg* **1974**;41:377-379
6. Waga S, Morikawa A. Aneurysm developing on the infundibular widening of the posterior communicating artery. *Surg Neurol* **1979**:125-127
7. Archer CR, Silbert S. Infundibula may be clinically significant. *Neuroradiology* **1978**;15:247-251
8. West HH, Mani RL, Eisenberg RL, Tuerk K, Stucker TB. Normal cerebral arteriography in patients with spontaneous subarachnoid hemorrhage. *Neurology* **1977**;27:592-594
9. Locksley HB, Sahs AL, Sandler R. Report on the cooperative study of intracranial aneurysm and subarachnoid hemorrhage. III. Subarachnoid hemorrhage unrelated to intracranial aneurysm and a-v malformation. *J Neurosurg* **1966**;24:1034-1056
10. Pakarinen S. Incidence, aetiology, and prognosis of primary subarachnoid hemorrhage. *Acta Neurol Scand* **1967**;43 [suppl 29]:1-128
11. Perret LV, Bull JWD. The accuracy of radiology in demonstrating ruptured intracranial aneurysms. *Br J Radiol* **1959**;32:85-92
12. Schunk H. Spontaneous thrombosis of intracranial aneurysms. *AJR* **1964**;91:1327-1338
13. Hayward RD. Subarachnoid hemorrhage of unknown aetiology. *J Neurol Neurosurg Psychiatry* **1977**;40:926-931
14. Forster DMC, Steiner L, Hakanson S, Bergvall U. The value of repeat pan-angiography in cases of unexplained subarachnoid hemorrhage. *J Neurosurg* **1978**;48:712-716
15. Winn HR, Richardson AE, Jane JA. The long-term prognosis in untreated cerebral aneurysms. I. The incidence of late hemorrhage in cerebral aneurysms: a 10-year evaluation of 364 patients. *Ann Neurol* **1977**;1:358-370