

The **next generation** GBCA
from Guerbet is here

Explore new possibilities >

Guerbet | 

© Guerbet 2024 GUOB220151-A

AJNR

Lumbar Myelography with Metrizamide: Supplemental Techniques

Hyo S. Ahn and Arthur E. Rosenbaum

AJNR Am J Neuroradiol 1981, 2 (1) 91-95

<http://www.ajnr.org/content/2/1/91>

This information is current as
of July 15, 2024.

Lumbar Myelography with Metrizamide: Supplemental Techniques

Hyo S. Ahn¹
Arthur E. Rosenbaum^{1, 2}

In a pilot group of 20 sequential patients who underwent metrizamide lumbar myelography, three modifications in technique were compared: (1) a "30" min delayed frontal projection, (2) supine projection of the conus medullaris, and (3) horizontal beam oblique views of the lumbosacral theca. The study showed much better opacification of the lowermost lumbar and the sacral root sleeves by delayed filming in most (70%) of the cases; that the conus medullaris, a structure difficult to visualize by the routine method of prone positioning, could be well visualized routinely with the patient supine; and that larger numbers of lumbar nerve root sleeves could be seen with the same degree of table tilt on horizontal beam oblique than on vertical beam oblique radiography.

The early clinical use of water-soluble contrast agents, Abrodil, Skiodan, Contrast U (trade brands of methiodal sodium), afforded excellent opacification of the lumbar subarachnoid space and demonstrated more lateral extension of the respective nerve root sleeves than Lipiodol [1]. The advent of the first clinically tested nonionic water-soluble myelographic medium, metrizamide (Amipaque, Winthrop Labs., New York, NY) obviated most of the hazards associated with previous water-soluble ionic myelographic agents [2, 3].

Despite the miscibility of metrizamide with cerebrospinal fluid, its usually lower inherent radiodensity, rapid dilution, and elusiveness on displacement have posed problems for myelographers recently exposed to water-soluble agents. Special techniques have been used to overcome some of these deficiencies [4-11]. We describe and demonstrate three more radiographic techniques for further enhancing the value of myelography with metrizamide, the prototype nonionic agent.

Subjects and Methods

Lumbar myelography with metrizamide was performed in 20 consecutive patients. There were 13 men and seven women 18-75 years old (mean, 39 years). In each the lumbar subarachnoid puncture was made at the L3 level under fluoroscopic guidance, following which 12-14 ml of metrizamide (190 mg I/ml concentration) was introduced with the patient in the prone position. After slowly injecting the contrast material (over a 2-3 min interval), prone vertical-beam oblique films were obtained with the table elevated 10°-20° head-up, followed by posteroanterior, horizontal-beam oblique, and lateral views. Then the tabletop was tilted to bring metrizamide to the lower thoracic and upper lumbar region and a frontal view was exposed to visualize the conus medullaris. Periodic fluoroscopic control was used. The patient was still prone for this radiograph.

Immediately thereafter, the table was elevated 10°-20° head-up, and the lumbar puncture needle was removed. Each patient was then turned supine. Under fluoroscopic control, the contrast medium was collected in the lower thoracic and upper lumbar subarachnoid space and another frontal film was obtained centered at the conus medullaris. Then the contrast medium was brought down to the lumbosacral thecal sac. About 30 min

Received April 10, 1980; accepted after revision August 22, 1980.

¹Department of Radiology, Neuroradiology Division, University of Pittsburgh School of Medicine, and Presbyterian-University Hospital, DeSoto at O'Hara Sts., Pittsburgh, PA 15213. Address reprint requests to H. S. Ahn.

²Present address: Department of Radiology, Neuroradiology Division, Johns Hopkins Hospital, Baltimore, MD 21205.

This article appears in January/February 1981 *AJNR* and March 1981 *AJR*.

AJNR 2:91-95, January/February 1981
0195-6108/81/0021-0091 \$00.00
© American Roentgen Ray Society

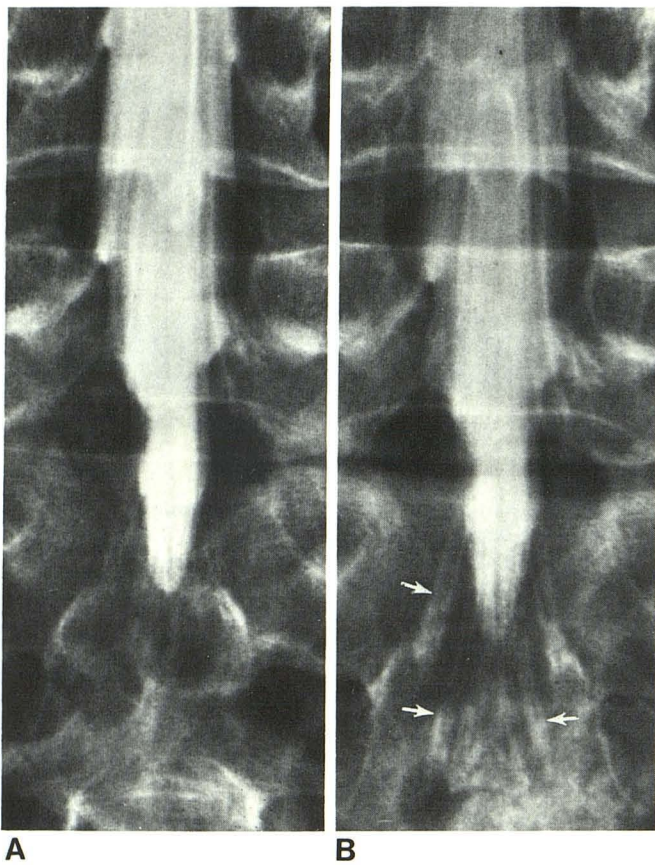


Fig. 1.—A, Initial film after metrizamide instillation. B, 30 min delayed film. Lower lumbar and sacral root sheaths of greater length and density (arrows). Density of contrast medium in thecal sac diminished.

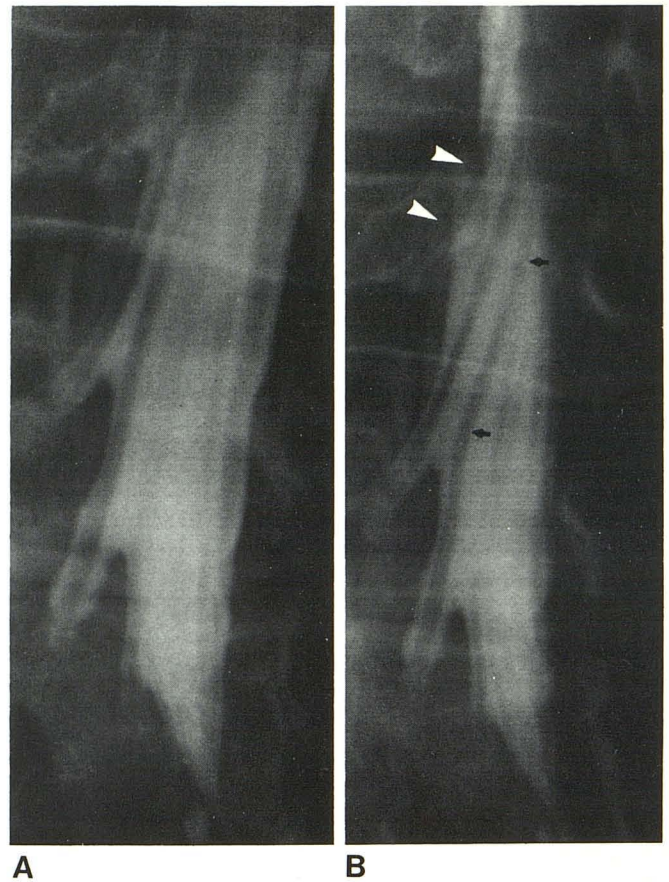


Fig. 2.—A, Vertical-beam oblique projection. B, Horizontal-beam oblique projection. Individual spinal nerves in thecal sac more clearly visible (arrows). Increased number of opacified root sleeves without change in table tilt. (See L4 root sleeve, arrowheads.) This projection proved particularly useful with large thecal sac.

TABLE 1: Changes in Length of Contrast-Filled Root Sleeves on Delayed Films

Nerve Roots	Length on Delayed Film (no./%) (n = 40)		
	Increase	Decrease	No Change
L3	18 (45)	6 (15)	16 (40)
L4	29 (73)	5 (12)	6 (15)
L5	32 (80)	3 (8)	5 (12)
S1	31 (77)	3 (8)	6 (15)
S2	29 (73)	4 (10)	7 (17)
Total	139 (70)	21 (10)	40 (20)

after injection of metrizamide, the patient was turned prone and another posteroanterior view (delayed film) of the lumbosacral region was obtained with the radiographic equipment and factors described above.

Results

Delayed Filming

The initial and delayed frontal (posteroanterior) films were reviewed and assessed as to the degree of filling of the lumbar and sacral root sleeves. The length of the root sleeves was determined by measuring the distance from the

lateral aspect of the thecal sac to the most distal part of contrast-filled root sleeve. Any alterations in the length of the root sleeves occurring between the initial and delayed films were scrutinized (table 1).

Of the 200 root sleeves assessed (five levels from L3 to S2, right and left sides, 20 cases), increase in length of opacification occurred on delayed films (fig. 1) in 70% of instances. In 20% there was no change in length of filling of the root sleeves. Decreased filling length was observed in 10%. The L5 and S1 root sleeves, those most frequently affected by discogenic disease in man, were better filled in 80% and 77%, respectively, on delayed films. Improved visualization of L3 and L4 root sleeves was noted in 45% and 73% of the cases, respectively. The L1 and L2 root sleeves were usually poorly opacified and precise measurements could not be obtained.

Nerve Roots and Conus Medullaris

Visual inspection rather than numerical measurement was used to compare visualization between the vertical- and horizontal-beam oblique projections of the nerve roots. Sim-

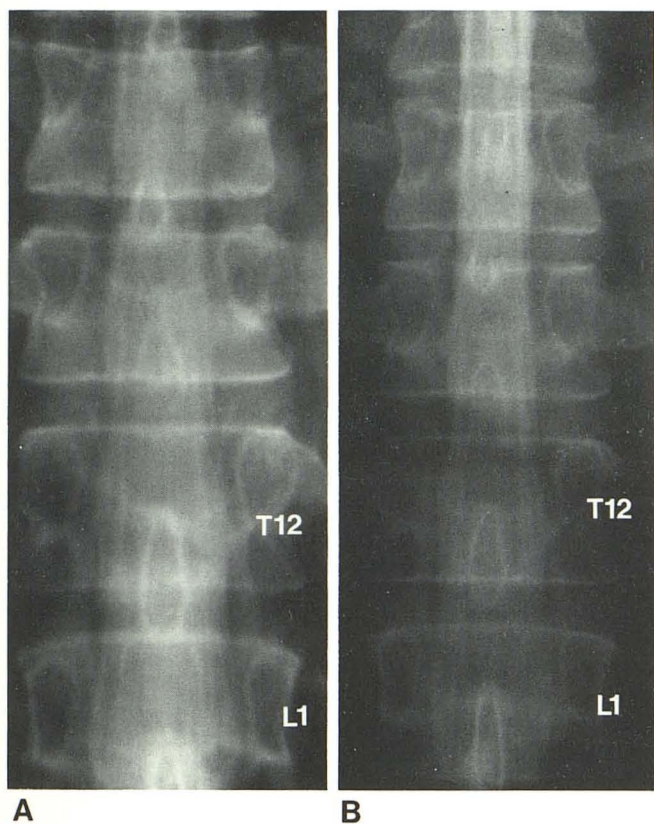


Fig. 3.—A, Prone view of conus medullaris. Nerves of cauda equina well seen. Conus medullaris not shown well because insufficient contrast medium surrounds posterior aspect. B, Supine view. Better visualization of conus, lying posteriorly with surrounding contrast medium.

ilar criteria were used to evaluate the supine and prone projections of the conus medullaris. In every instance, visualization of the nerve roots appeared superior on the horizontal-beam views (fig. 2) and the conus medullaris was much better seen with the patient supine (fig. 3).

Discussion

Delayed Filming of Nerve Roots

Frustrating experiences with water-soluble contrast media for myelography have amply shown the necessity of modifying techniques that were developed for oil-soluble contrast media [6, 10]. Hindmarsh [12] and others [5, 13, 14] demonstrated that a sufficient amount of contrast medium within the lumbar subarachnoid space could be radiographed even 1 hr after injection. This prolonged visualization depends on the concentration and volume of the metrizamide instilled relative to the capaciousness of the sac, the vigorousness of cerebrospinal fluid pulsations, and the positions in which the patient is placed after the contrast material is in situ.

In our study, there proved to be not only sufficient contrast media remaining within the lumbosacral theca on the 30 min delayed film but diagnostic advantage in delayed filming,

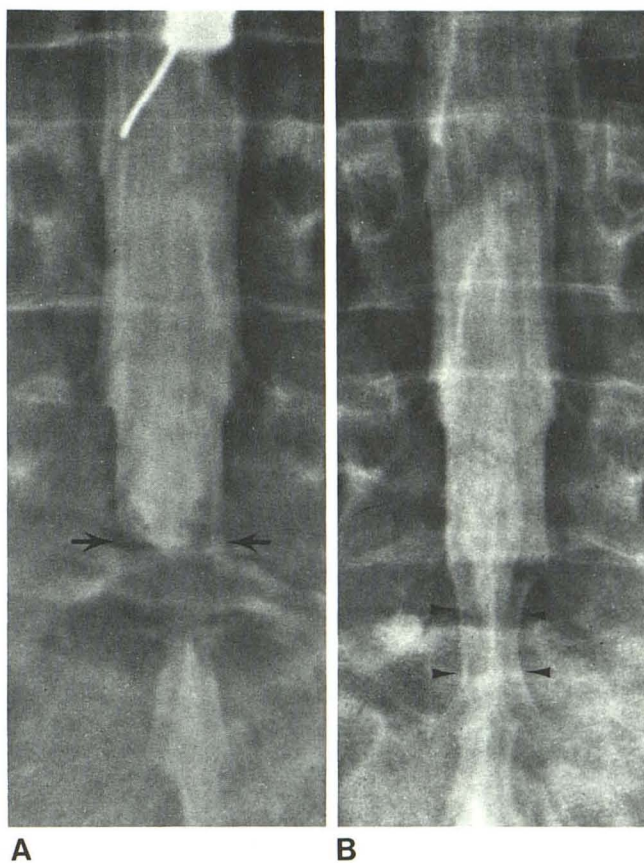


Fig. 4.—A, Initial frontal view. High-grade, incomplete block at L5-S1 intervertebral level with poorly defined lower margin of upper contrast column (arrows). B, Delayed film. Greater filling of thecal sac deformed by extradural process (arrowheads).

which showed a dense and longer segment opacification of the lower lumbar and sacral root sleeves (fig. 1). Since superior visualization of the lower lumbar and sacral root sleeves was observed frequently, a routine delayed film would seem propitious whenever conventional films of the lumbar and sacral roots have not satisfied the clinical inquiry.

Delayed filming also better demonstrated the inferior side of a substantial subarachnoid block (fig. 4) and resulted in better filling of sacral root cysts (fig. 5). Lumbar epidural venography has been useful when oil myelographic results were equivocal, but it has been required less frequently since water-soluble myelographic media were made available in North America. However, equivocal results with water-soluble media may still call for this additional procedure. With delayed films this recourse may seldom be required.

Improved Visualization of the Conus Medullaris

Demonstration of the conus medullaris has been considered mandatory in lumbar myelography [15]. However, the biphasic curvature of the thoracolumbar juncture militates

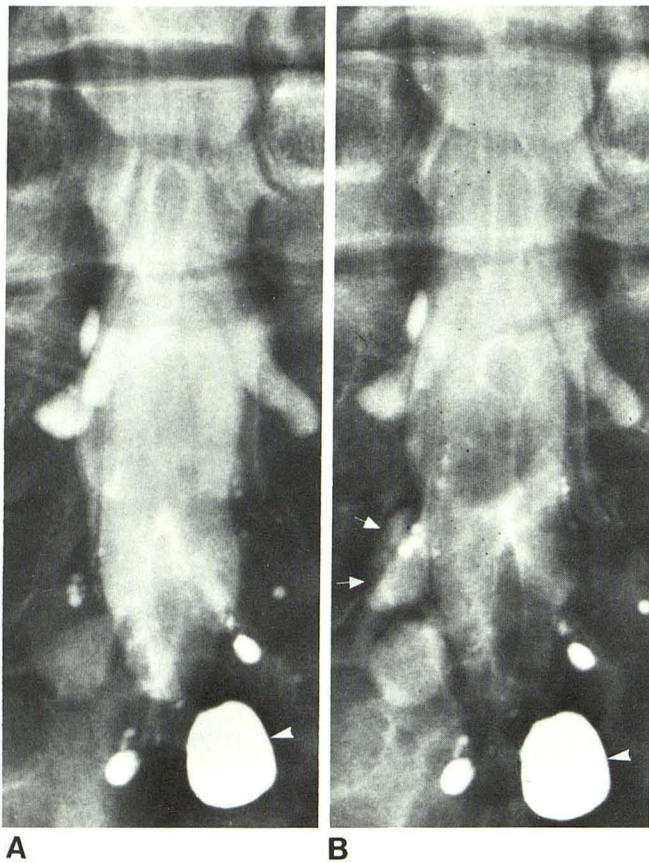


Fig. 5.—Delayed filling of perineural sacral root cysts. A, Initial film. B, 30 min delayed film. Cyst at left S2 level opacified only on delayed film (arrows). Marked increase in density of another cyst at left S3 level. Another cyst (arrowhead) contains residual iophendylate from previous myelography.

against dependent pooling of the myelographic medium in the lower dorsal and upper lumbar region when the patient is in the prone position. Moreover, the conus medullaris usually lies in the dorsal aspect of the theca. These facts and the physical characteristics of a water-soluble contrast agent nullify the value of the prone position for regular visualization of the conus region. However, as in iophendylate myelography, the conus is usually not seen in the absence of a block unless the patient is placed supine, with or without the needle in place (on a special block), or a high volume of iophendylate is used.

The use of fluoroscopy to assist accurate pooling of the metrizamide in the supine position resulted in very good visualization of the conus medullaris in each of our cases (figs. 3 and 6). Recently, Russell et al. [16] reported excellent visualization of the thoracic cord and conus medullaris in supine metrizamide myelography. Tomography can also be used to enhance visualization of the conus region (fig. 7).

Horizontal-Beam Oblique Projection of Lumbar Nerve Root

In North America, the lumbar nerve roots are usually radiographed by vertical-beam, fluoroscopically positioned

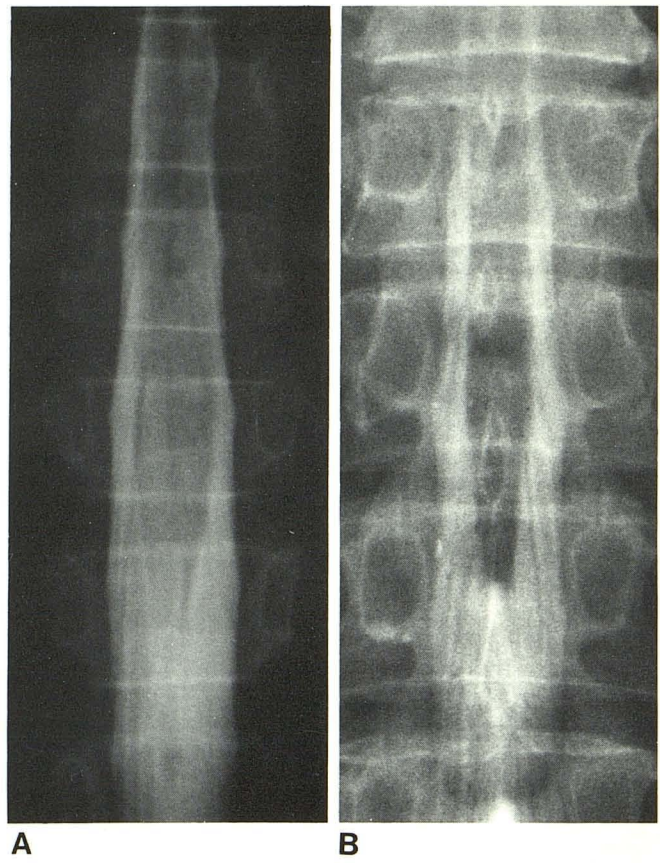


Fig. 6.—Supine views of conus medullaris in two cases. Excellent demonstration of lumbar enlargement, conus medullaris, and cauda equina.

spot films. Many investigators in Scandinavia [5, 7, 10] have stressed the value of horizontal-beam views of these lumbar nerve roots. Horizontal oblique projections have become standard for the cervical nerve roots; the lumbar roots are also seen best by horizontal-beam oblique views.

In order to get a good horizontal-beam oblique view, the patient should be in a more oblique position compared with the position needed for vertical oblique view. This steeper obliquity brings the root sleeves into dependent position, which may encourage better filling of root sleeves by gravity. Further, a larger number of root sleeves can be visualized on single film with the same degree of table tilt (fig. 2), thus reducing the frequency of extra films and minimizing table tilting. We believe it follows that the horizontal-beam technique should replace the vertical-beam technique for evaluation of herniated intervertebral discs.

REFERENCES

1. Arnell S, Lidstrom F. Myelography with Skiodan (Abrodil). *Acta Radiol (Stockh)* 1931;12:287-289
2. Amundsen P. Myelography and radiculography—development of new contrast media. *Wis Med J* 1977;76:63-67
3. Metrizamide. *Acta Radiol [Suppl] (Stockh)* 1973;335:1-390

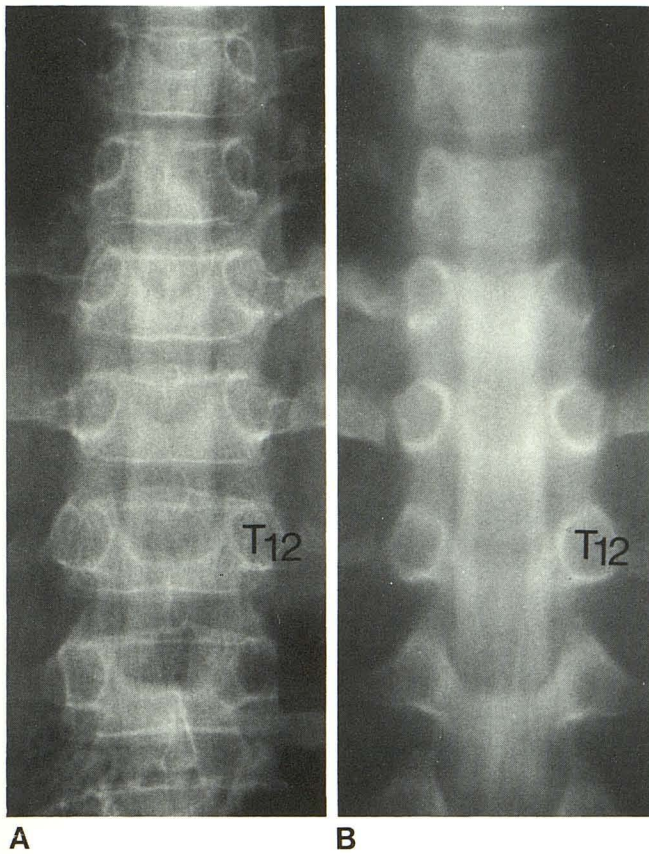


Fig. 7.—Further enhancement by tomography. **A**, Conventional film. **B**, Multidirectional tomography. Conus medullaris only faintly visible with patient supine. After multidirectional tomography of opacified subarachnoid space, conus medullaris is well seen.

4. Gonsette RE. Metrizamide as contrast medium for myelography and ventriculography. Preliminary clinical experiences. *Acta Radiol [Suppl]* (Stockh) **1973**;335:346-358
5. Hindmarsh T. Myelography with the non-ionic water-soluble contrast medium-metrizamide. *Acta Radiol [Diagn]* (Stockh) **1975**;16:417-435
6. Sackett JF. Myelographic technique with water-soluble contrast media. In: Sackett JF, Strother CM, eds. *New techniques in myelography*. Hagerstown, MD: Harper & Row, **1979**:45-68
7. Skalpe IO, Amundsen P. Lumbar radiculography with metrizamide. *Radiology* **1975**;115:91-95
8. Kieffer SA, Binet EF, Esquerre JV, Hantman RP, Gross CE. Contrast agents for myelography: clinical and radiological evaluation of Amipaque and Pantopaque. *Radiology* **1978**;129:695-705
9. Dugstad G, Eldevik P. Lumbar myelography. *Acta Radiol [Suppl]* (Stockh) **1977**;355:17-30
10. Grainger RG. Technique of lumbar myelography with metrizamide. *Acta Radiol [Suppl]* (Stockh) **1977**;355:31-37
11. Lindblom K. Lumbar myelography by Abrodil. *Acta Radiol* (Stockh) **1946**;27:1-7
12. Hindmarsh T. Methiodal sodium and metrizamide in lumbar myelography. *Acta Radiol [Suppl]* (Stockh) **1973**;335:359-366
13. Skalpe IO, Torbergesen T, Amundsen P, Presthus J. Lumbar myelography with metrizamide. *Acta Radiol [Suppl]* (Stockh) **1973**;335:367-379
14. Svare A, Talle K. Lumbar myelography with metrizamide. *Acta Radiol [Suppl]* (Stockh) **1973**;335:387-390
15. Taveras JM, Wood EH. *Diagnostic neuroradiology*, 2d ed, Baltimore, MD: Williams & Wilkins, **1976**:1107
16. Russell EJ, Pinto R, Kricheff II. Supine metrizamide myelography: a technique for achieving excellent visualization of the thoracic cord and conus medullaris. *Radiology* **1980**;135:227-228