

Are your **MRI contrast agents** cost-effective?

Learn more about generic **Gadolinium-Based Contrast Agents**.



**FRESENIUS
KABI**

caring for life

AJNR

Primary malignant melanoma in the oral mucosal membrane with metastasis in the cervical lymph node: MR appearance.

Y Uchiyama, S Murakami, T Kawai, T Ishida and H Fuchihata

This information is current as of June 30, 2024.

AJNR Am J Neuroradiol 1998, 19 (5) 954-955
<http://www.ajnr.org/content/19/5/954>

Primary Malignant Melanoma in the Oral Mucosal Membrane with Metastasis in the Cervical Lymph Node: MR Appearance

Yuka Uchiyama, Shumei Murakami, Tadahiko Kawai, Takeshi Ishida, and Hajime Fuchihata

Summary: We report a case of oral malignant melanoma with metastasis to the cervical lymph node. The MR appearance corresponded to previously reported MR characteristics of malignant melanoma in other regions. Both the primary tumor and the nodal metastasis showed high signal intensity on T1-weighted images.

Malignant melanoma arises from melanocytes (1). Malignant melanoma in the oral cavity accounts for 0.2% to 8% of all malignant melanomas (2). In Japan, oral malignant melanoma is relatively common, with about 50% of cases occurring in the hard palate and the upper gingiva (3). Metastases from malignant melanoma occur in the regional lymph nodes and in such distant sites as the lung, liver, brain, and bone (3).

Prognosis for malignant melanoma in the oral region is poorer than its counterpart in cutaneous regions because of anatomic considerations and delayed diagnosis (1). The prognosis is closely related to tumor thickness and to the accompanying 50% prevalence of regional metastasis at presentation. It is difficult to assess the extent of a suspected malignant melanoma, although treatment and prognosis depend on establishing the extent of disease and the presence or absence of metastasis, such as in the regional lymph nodes.

CT scans depict malignant melanoma as an expansile, homogeneously enhancing mass (4). Melanin has paramagnetic properties that can affect signal on MR images, on which melanotic melanomas have a characteristic intensity pattern: they appear hyperintense on T1-weighted sequences and hypointense on T2-weighted sequences (4).

We report a case of a primary lesion on the hard palate with metastasis in the cervical lymph nodes. We describe the MR and CT characteristics of the lesion and discuss its unique appearance on MR images.

Case Report

A 60-year-old man was referred to us because of pigmented patches, with bleeding, on the right side of the hard palate. Physical examination revealed a pigmented region with a small bulge and some scattered ulceration on the upper right portion of the palate. The lesion was 30 mm in diameter. The patient's medical history included diabetes mellitus controlled by drugs; otherwise, he had been in good health.

A coronal CT scan showed erosion of the right maxillary alveolus (Fig 1A), but no visible mass. An upper cervical lymph node greater than 25 mm in diameter was seen on axial CT scans (Fig 1B and C). On a contrast-enhanced CT study the node enhanced slightly and was inhomogeneous (Fig 1C).

MR imaging was performed with a superconductive MR unit (Vista-E50; Fuji Electric, Japan) at 0.5 T. We used a circularly polarized head coil specialized for the head and facial regions developed at our institution. The node appeared hyperintense on an unenhanced T1-weighted coronal image (Fig 1D), and a contrast-enhanced T1-weighted coronal image showed greater hyperintensity on the right upper alveolar bone (Fig 1E). The signal intensity of the tumor was intermediate or hypointense on a T2-weighted coronal image of the same region (Fig 1F). A noncontrast T1-weighted coronal image showed high signal intensity of the upper jugular node (Fig 1G), and a contrast-enhanced T1-weighted image was slightly higher in signal. The lymph node measured more than 25 mm in diameter (Fig 1H). On a T2-weighted coronal image, the lymph node was of intermediate signal intensity (Fig 1I).

The patient underwent partial maxillectomy and right-sided radical neck dissection and was administered a chemotherapeutic agent (OK-432) before and after surgery.

Histologic examination showed a diffuse proliferation of cells with a spindle-cell pattern. Melanin pigment was identified within the cytoplasm. The oral epithelium was partly ulcerated, part of the tumor was exposed, and bone destruction was evident. Histopathologically, the lesion was a malignant melanoma.

The excised area was covered with an upper denture, and the patient was followed up regularly and has been free of disease, with no clinical evidence of primary recurrence or metastasis, for 1½ years.

Discussion

Malignant melanoma in the oral cavity affects all races (2). About 50% of patients have enlarged cervical nodes when first examined, and regional lymph

Received November 5, 1996; accepted after revision June 17, 1997.

Presented in part at the Japanese Society for Oral and Maxillofacial Radiology, Gifu, Japan, May 1995.

From the Department of Oral and Maxillofacial Radiology, Faculty of Dentistry Osaka University (Y.U., S.M., T.K., H.F.), and the Department of Clinical Laboratory, Osaka University Dental Hospital (T.I.), Japan.

Address reprint requests to Yuka Uchiyama, DDS, Department of Oral and Maxillofacial Radiology, Faculty of Dentistry Osaka University, 1-8, Ymadaoka, Suita, Osaka 565, Japan.

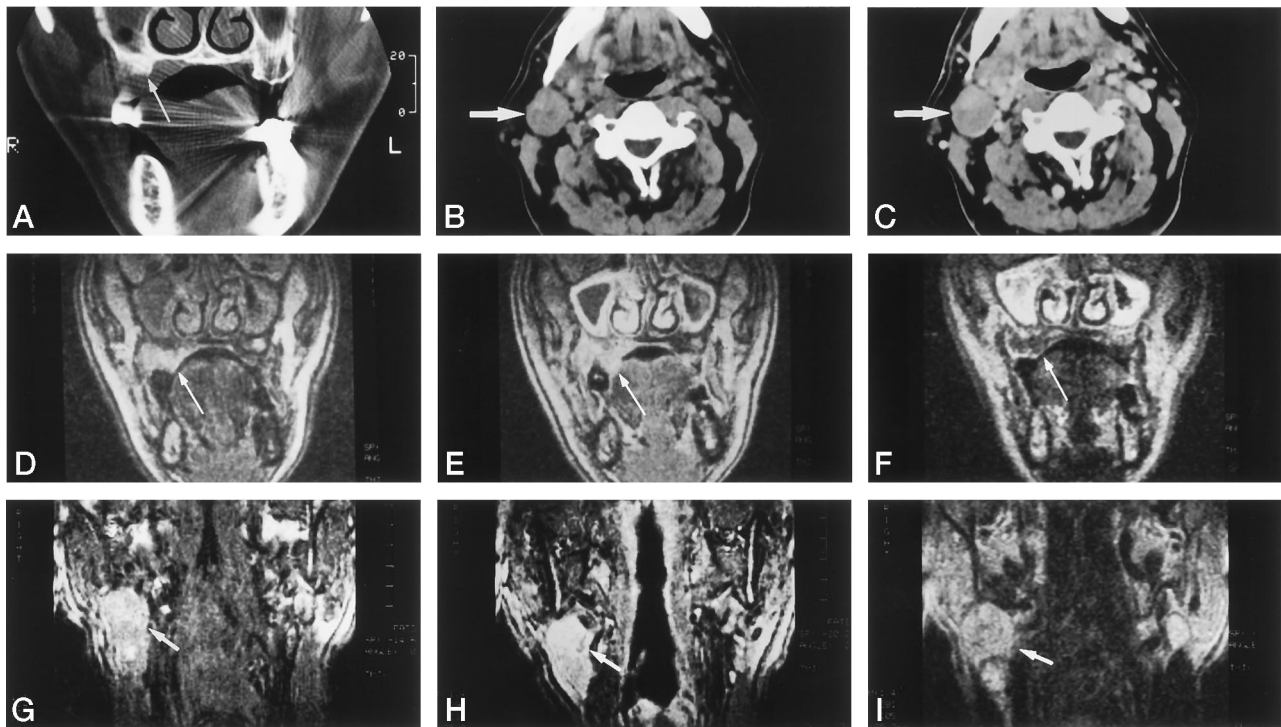


FIG 1. 60-year-old man with pigmented patches, bleeding, a small bulge, and scattered ulceration on the right side of the hard palate.
 A, Coronal CT scan shows bone destruction on the upper right (arrow).
 B, Axial CT scan shows an upper cervical lymph node greater than 25 mm in diameter (arrow).
 C, Contrast-enhanced CT scan shows slightly inhomogeneous enhancement in a lymph node in the neck (arrow).
 D, Coronal T1-weighted MR image (670/25/2 [TR/TE/excitations]) shows hyperintensity on the right upper alveolar bone (arrow).
 E, Contrast-enhanced coronal T1-weighted MR image (670/25/2) is more hyperintense (arrow) than corresponding unenhanced image.
 F, Coronal T2-weighted MR image (2000/90/2) shows intermediate or hypointense signal intensity (arrow).
 G, T1-weighted MR image (670/25/2) shows high signal intensity in a right-sided subdigastic lymph node of more than 25-mm diameter (arrow).
 H, Contrast-enhanced T1-weighted MR image (670/25/2) shows slightly higher signal intensity (arrow) than corresponding unenhanced image.
 I, Coronal T2-weighted MR image (2000/90/2) shows intermediate signal intensity of lymph node within the nodal mass (arrow).

node metastasis occurs in about 75% of patients some time in the course of the disease (3).

Our patient underwent both MR and CT examinations. The CT scans revealed bone destruction in the upper right region and a lymph node of more than 25 mm in the upper cervical area; these findings were considered representative of regional metastasis. At MR imaging, both primary lesion and metastatic node were hyperintense on the T1-weighted image and intermediate to hypointense on the T2-weighted image. In the head and neck region, as previously reported, the MR findings of melanoma, although variable, are characterized by hyperintense T1-weighted images and intermediate to hypointense T2-weighted images, owing to its paramagnetic effects (presumably related to chelated metal ions or free radicals known to exist in melanin) (5-7). The MR findings in the primary lesion in our case corresponded to MR characteristics reported previously. The MR intensity of the cervical lymph node was similar to that of the primary lesion both on T1- and T2-weighted sequences.

Results of the MR examination suggested a malignant melanoma with nodal metastasis, and pathologic diagnosis was malignant melanoma. Therefore, the MR appearance was consistent with the histopathologic finding.

Conclusion

Because the CT findings of malignant melanoma are not specific, diagnosis by this method cannot be considered confirmatory. This case suggests that in some cases the presence of metastasis from malignant melanoma can be established by the unique MR characteristics of malignant melanoma. More experience is needed to determine how often this effect is present.

References

1. Ishikawa G. *Oral Pathology II*. 2nd ed. Kyoto: Suenaga Syoten; 1986:676-679
2. Strauss JE, Strauss SI. **Oral malignant melanoma: a case report and review of literature.** *J Oral Maxillofac Surg* 1994;52:972-976
3. Lucas RB. *Pathology of Tumours of the Oral Tissues*. 4th ed. New York: Churchill Livingstone; 1984:276-281
4. Rao VM, Flanders AE, Tom BM. *MR and CT Atlas of Correlative Imaging in Otolaryngology*. United Kingdom: Martin Dunitz; 1992;3, 6, 318-319
5. Gomori JM, Grossman RI, Shields JA, et al. **Chorioidal melanomas: correlation of NMR spectroscopy and MR imaging.** *Radiology* 1986; 158:443-445
6. Woodruff WW, Djang WT, McLoendon RE, et al. **Intracerebral malignant melanoma: high-field-strength MR imaging.** *Radiology* 1987;165:209-213
7. Atlas SW, Grossman RI, Gomori JM, et al. **MR imaging of intracranial metastatic melanoma.** *J Comput Assist Tomogr* 1987;11: 577-582