

Are your **MRI contrast agents** cost-effective?

Learn more about generic **Gadolinium-Based Contrast Agents**.



**FRESENIUS
KABI**

caring for life

AJNR

Epilepsy for the neuroradiologist.

R S Fisher, A Stein and J Karis

AJNR Am J Neuroradiol 1997, 18 (5) 851-863

<http://www.ajnr.org/content/18/5/851.citation>

This information is current as
of June 30, 2024.

Epilepsy for the Neuroradiologist

Robert S. Fisher, Alan Stein, and John Karis

Diagnosis and treatment of epilepsy, once the sole purview of the general practitioner or neurologist, has in recent years become a team effort. Modern management of epilepsy now benefits from the services not only of neurologists or subspecialized epileptologists, but also of specialized nursing personnel, surgeons, neuropsychologists, social workers, and counselors. Especially important is the input of a neuroradiologist with expertise in epilepsy. As will be seen below, neuroradiologic studies have become of key importance in identifying underlying causes of epilepsies and in assisting the multidisciplinary approach to locate the seizure focus or foci in the brain. Very recent advances also suggest that neuroradiologic studies will be important in mapping functional regions of the brain, which should be spared during seizure surgery.

This article will provide an overview of epilepsy for the neuroradiologist. As a new member of the epilepsy team, the neuroradiologist should have familiarity with the different types of seizures, the usual causes of seizures, the clinical approach to diagnosis and therapy of epilepsy, and specific ways in which neuroradiologic studies can aid these processes.

General Background

A seizure is a paroxysmal dysfunction caused by an abnormal electrical discharge in the brain. The seizure results in a sudden and stereotyped alteration of sensory motor function, behavior, memory, or consciousness. Epilepsy is the condition of spontaneously recurrent seizures. Epilepsy is a family of disorders, not a specific disease.

Epilepsy is more common than generally rec-

ognized by most physicians outside of the field and is the most prevalent serious neurologic disorder that affects people of all ages. Between 0.5% and 1% of the world's population has epilepsy. As many as 5% to 10% of persons will experience one or more seizures in their lives; in most of these people, epilepsy will not develop (1). The number of people who have other events considered possibly to be epilepsy is even larger, but unknown. These events include spells of confusion, blackouts of unknown cause, unusual movements, and episodic paroxysmal events.

Etiology

Seizures result from an imbalance between excitation and inhibition in the brain (2). In some seizure types this imbalance favors excitation, in others (mainly absence or petit mal), inhibition. During seizure discharges, neurons in the brain fire excessively and in a disordered fashion, reflecting abnormal synchronous bursting of neurons. The zone of origin of seizures in the brain is called the *seizure focus*. A hyperexcitable seizure focus can recruit normal neurons and circuits into the seizure pattern.

Causes of epilepsy fall into categories of *generalized* metabolic disturbances to brain, and *focal* insults to brain. Table 1 lists the usual etiologic factors of generalized or focal epileptogenic brain processes. Most instances of epilepsy are idiopathic (no specific cause can be determined) (3, 4).

Seizure Types

The manifestations of a seizure depend on several factors, including the age of the patient,

From the Departments of Neurology (R.S.F., A.S.) and Radiology (J.K.), Barrow Neurological Institute Phoenix, Ariz, and the University of Arizona College of Medicine, Tucson (R.S.F.).

Dr Fisher receives support from the Sandra Solheim Aiken Fund for Epilepsy and the Womens' Board of the Barrow Neurological Foundation. Dr Stein is the Wilder Penfield Fellow of the Epilepsy Foundation of America, supported by Novartis.

Address reprint requests to Robert S. Fisher, MD, PhD, Director, Epilepsy Center, Barrow Neurological Institute/SJHMC, 350 W Thomas Rd, Phoenix, AZ 85013-4496.

Index terms: Seizures; Special reports

TABLE 1: Usual causes of generalized and focal seizures

Cause	Generalized Seizures	Focal Seizures
Idiopathic (genetic)	Absence, myoclonic, neonatal convulsions	Benign focal epilepsies of childhood
Metabolic	Hypoglycemia, hypocalcemia, hypomagnesemia, hyponatremia or hypernatremia, inborn errors of metabolism	Hyperglycemia, mitochondrial disorders
Cerebral injury	Anoxic ischemic, lead poisoning	Stroke, tumor, focal trauma
“Developmental” abnormalities	Intrauterine infections, intrauterine ischemia	Migration defects/heterotopias, mesial temporal sclerosis
Drug or toxin	Alcohol-related seizures, drug withdrawal (barbiturate, benzodiazepine), drug toxicity (lidocaine, penicillin, isoniazid)	...
Infection	...	Meningitis, abscess, encephalitis

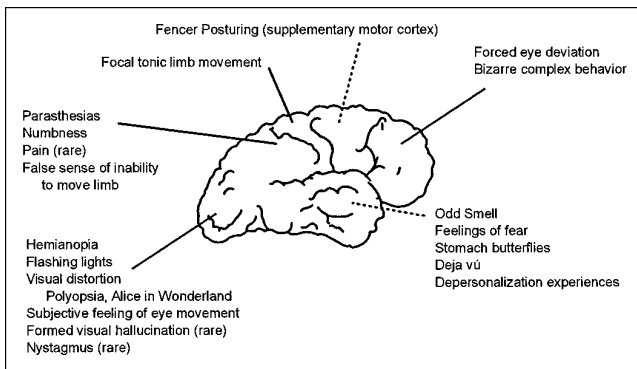


Fig 1. The the typical symptoms of seizures originating in various areas of the brain.

whether the patient is waking or sleeping, hormonal cycles in women, presence of medications, and other largely ill-understood factors. The most important factor is the location of the seizure focus (where in the brain the abnormal electrical activity originates) and how far it spreads throughout normal brain. Figure 1 illustrates typical symptoms of seizures originating in various sensory-motor or association areas of brain. The international classification of seizures is listed in Table 2 (5, 6).

Seizures are divided into those that are apparently generalized from the start and those that start focally (partially). The yet-unproved presumption about so-called primary generalized seizures is that they originate subcortically, perhaps in the thalamus, and are projected, and appear on electroencephalography (EEG) simultaneously over different regions of cortex (7). Partial seizures, on the other hand, start in one part of the brain and appear focally on EEG.

The partial seizures are subdivided into *simple seizures*, in which there is no loss of consciousness or awareness, and *complex seizures*, in which consciousness, awareness, or memory are impaired. Partial seizures can have motor,

TABLE 2: The International League against Epilepsy classification of seizures, 1981 revision

Partial (focal) seizures
Simple (consciousness preserved)
Simple motor
Simple sensory
Simple autonomic
Simple psychic
Simple mixed
Complex (consciousness altered)
With simple partial onset
With impaired consciousness from the start
Partial evolving to secondarily generalized
Generalized seizures
Absence, typical
Absence, atypical
Tonic and/or clonic
Atonic
Myoclonic
Unclassified seizures

sensory, or psychic manifestations, including somatosensory, auditory, visual, olfactory, or vestibular sensation, internal visceral sensation, autonomic symptoms, such as flushing or sweating, psychic disturbances (deja vu, perceptual distortions, fear, etc), or mixed symptoms. The autonomic-visceral and psychic simple partial seizures frequently progress to the point where they affect consciousness or awareness. In these instances, partial simple seizures serve as “auras” for *complex partial seizures*. Complex partial seizures, previously referred to as *psychomotor seizures*, *temporal lobe seizures*, or *limbic seizures*, may or may not have auras, and may or may not be associated with automatic behavior such as lip smacking, fumbling, vocalization, or persistence of ongoing activities. A complex partial seizure with no auras and no automatisms presents simply as an interruption of behavior with loss of memory of the event afterward. A complex partial seizure can, as can any seizure that begins focally, sec-

ondarily generalize to a full-blown tonic-clonic seizure.

Generalized seizures are subdivided into several categories. The generalized *tonic-clonic* (or *tonicoclonic*) seizure, previously called the *grand mal seizure*, involves stiffening with immediate loss of consciousness followed by a stage of rhythmic clonic jerking. Typical *absence seizures* present as brief staring spells with an immediate return to consciousness; they usually last a few seconds. These seizures used to be called *petit mal seizures*, and usually have their onset in childhood. Atypical absence continues for longer than a few seconds, involves falling, or has more complex automatisms and can be difficult to distinguish from complex partial seizures.

Seizures can present with isolated tonic activity or clonic activity. The *tonic supplementary motor seizure*, a focal seizure, is especially common. In this instance the subject exhibits a "fencer's posture," extending one arm, looking down that arm, and flexing the opposite arm above the head. Head turning is usually contralateral but sometimes ipsilateral to the seizure focus in supplementary motor area seizures. Isolated clonic seizures are rare. *Atonic seizures* are epileptic drop attacks, most commonly in children with diffuse brain disease. *Myoclonus* refers to lightning-like muscle jerking typically occurring in the face and limbs, synchronously or multifocally. If jerking continues for a period (not specified in the conventional literature), then it is called a *myoclonic seizure*. Seizures can also be unclassified by virtue of poor description of the start of the event, or because the seizure type does not fall within the usual categories.

Classification of the seizure types is important for several reasons. First, it provides common terminology for clinical, trial, and research communication. Second, medications have different therapeutic roles for different seizure types (see below). Third, patients with focal seizures are potential candidates for epilepsy surgery, whereas surgery has much less of a role for the primary generalized seizure types, with the exception of corpus callosum resection for atonic seizures. Fourth, discovery of an underlying structural lesion is much more likely with partial than with generalized seizures, and therefore the neuroradiologic search is typically more extensive in patients with partial seizures. One caveat here is that some seizures that ap-

TABLE 3: Common imitators of epilepsy

Syncope
Cardiac
Vasovagal or reflex
Hypotensive
Cerebrovascular
Transient ischemic attack
Complex or classic migraine
Transient global amnesia
Sleep disorders
Narcolepsy
Sonambulism
Bruxism
Periodic movements of sleep
Cataplexy
Episodic dizziness
Benign positional vertigo
Meniere disease
Labyrinthitis
Endocrine
Hypoglycemia
Pheochromocytoma
Thyroid dysfunction
Carcinoid tumors
Movement disorders
Chorea and athetosis
Tics and Tourette syndrome
Focal dystonias
Tremor
Myoclonus
In infants and children
Gastroesophageal reflux (Sandifer)
Night terrors
Breath-holding spells
Psychiatric
Nonepileptic seizures
Panic attacks
Episodic dyscontrol
Psychosis

pear to be generalized from the start are really partial seizures with very rapid spread of activity, or so-called secondary bilateral synchrony (8), which can occur especially when the foci are in prefrontal areas or other "silent" regions of brain.

Clinical Approach

A physician typically goes through several stages in evaluation of a patient with possible epilepsy. The first challenge is to secure the diagnosis. Many conditions can imitate epilepsy (Table 3) (9). Such imitators include syncope, cardiac arrhythmias, hypoglycemia, vasospasm as a part of complicated migraine, narcolepsy, cataplexy or excessive daytime sleepiness, transient ischemic attacks, transient global amnesia, tics or tremors, episodic ver-

tigo, fluctuating delirium, panic attacks, hyperventilation, psychogenic seizures, malingering, and several other less common imitators. To make the diagnosis of epilepsy, a clinician needs to start with a good report of seizures. The history of an event sounding consistent with a seizure is more important than any of the subsequent studies done for epilepsy. There should be alteration of sensory-motor function, behavior, or consciousness, with a clear start and a finish over a few seconds to a few minutes. The episode should be relatively stereotyped and not triggered by behavioral or environmental events, with the exception of occasional seizures that are triggered by flashing lights or other environmental stimuli. Since the patient is often unaware of behavior during a seizure, reports from close observers becomes of key importance.

The EEG remains the most important diagnostic test for epilepsy, but unfortunately is an imperfect marker of the disorder. The EEG records voltages from paired electrodes spaced across the scalp, and characterizes signatures of seizure disorders known as *spikes*, *sharp waves*, *spike waves*, or *ictal evolving rhythms*. Just as there are several seizure types, there are several EEG patterns that mark epilepsy. The EEG recording can be *interictal* (between seizures), *ictal* (during a seizure), or *postictal* (within the few minutes after a seizure). A single EEG will be abnormal interictally in about 50% of people with epilepsy, but EEG sensitivity can rise to 80% with 3 or 4 recording sessions (10) or with the use of special electrodes, sleep deprivation, flashing lights, or hyperventilation. Normal interictal EEG findings never rule out epilepsy, and it is reasonable to treat people who have a good likelihood of a seizure even if they have normal interictal EEG findings. EEG findings are usually abnormal during a seizure, but a few percent of people will have false-negative EEG findings even during an ictal event, because of a deeply placed or very small seizure focus. Conversely, EEG findings can also be false-positives because some healthy people have spikes without ever having had a clinical seizure (numerous normal variants have the appearance of EEG spikes). The combination of one of the imitators of epilepsy and an overinterpreted EEG can lead to a lifetime of inappropriate medication with antiepileptic drugs.

Figure 2 shows an interictal EEG with spikes.

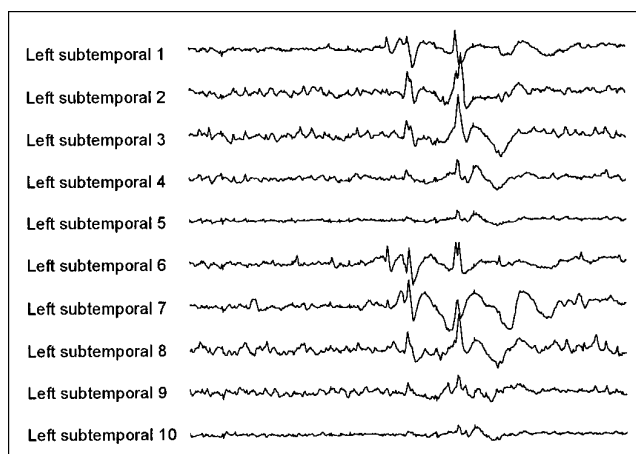


Fig 2. Interictal EEG with spikes arising from the mesial temporal lobe as seen with subtemporal grid electrodes.

Spikes help to confirm the impression of epilepsy in the proper clinical setting, to help classify the seizures as focal if the spikes are focal, and generalized if the spikes are widespread and generalized, and to indicate where seizures are likely to originate. Interictal spikes and sharp waves, which are like spikes but not as pointed, are markers of hyperexcitable tissue. They do not in themselves produce clinical manifestations, because they are briefer than a tenth of a second. Some patients who have frequent interictal spiking can, however, show subtle neuropsychological deficits. Similarly, interictal spiking does not significantly affect brain energy metabolism such as that detected with positron emission tomography, or cerebral blood flow as seen with single-photon emission computed tomography (CT) or functional magnetic resonance (MR) imaging.

Seizures assume a variety of forms, the most common of which have several possible EEG correlates. EEG during a seizure can show rhythmic buildup of spiking, spikes with associated slow waves in a rhythmic spike wave pattern, rhythmic sharp activity evolving in frequency and amplitude, or sometimes a paradoxical flattening (electrodecremental) of EEG activity at the site. Figure 3 illustrates an EEG seizure beginning over the left temporal lobe. Because most complex partial seizures originate in mesial temporal structures, there can be a lag between onset of behavior and visible scalp changes while the activity projects to the surface and recruits neurons involved in generation of the scalp EEG. This lag disappears when invasive depth electrodes are inserted into the medial temporal lobe structures. Partial and

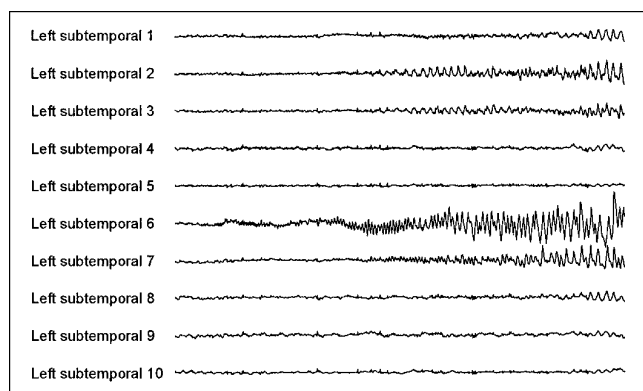


Fig 3. Ictal EEG with focal seizure arising from the mesial temporal lobe as seen with subtemporal grid electrodes.

secondary generalized seizures are associated with significantly increased cerebral blood flow and metabolism, detectable on studies sensitive to these changes.

Epilepsy Monitoring

Because a routine EEG typically lasts only 20 to 30 minutes, and is therefore unlikely to capture a seizure, technologies and methods have been developed for long-term video EEG monitoring. Patients are admitted to a specially equipped hospital room with television cameras and digitally recorded multichannel EEG. Computer algorithms are used to highlight electrical activity that has a signature suggesting spikes or seizurelike events for subsequent review. Behavior during a seizurelike event can then be compared with EEG activity. Epilepsy monitoring has two primary functions: the first is to secure a diagnosis of epilepsy and distinguish seizures from imitators when the clinical picture is unclear; the second is to locate a seizure focus in patients who might be candidates for epilepsy surgery. Several seizures need to be recorded to judge the consistency of onset of the seizure (11). Medications can be withheld in a monitoring unit in order to provoke seizures.

Magnetic recordings of brain activity have recently been used to supplement electrical recordings. Every time-varying electrical field is associated with a magnetic field, and vice versa, so the magnetic recordings are of fundamentally the same activity as the EEG. Nevertheless, the fields are at right angles to each other, and magnetic fields are not distorted by tissue interfaces of different conductivity as are the electrical fields. Therefore, magnetic recordings

are sometimes more useful in locating seizure foci (12). Problems with magnetoencephalography include the technical difficulty of obtaining a clear signal because of the extremely small size of the relevant magnetic field, and the need for various mathematical models, which may or may not be accurate, to interpret the source dipole. Magnetoencephalography at this point remains a research technique.

Intracranially implanted electrodes are a standard part of the recording armamentarium in epilepsy centers, and have been in use since the early 1950s (13). These electrodes comprise thin wires implanted stereotactically into either mesial temporal structures, deep frontal structures, or occasionally other lobes of the brain. Sheets (grids) of electrodes or strips of electrodes with disks embedded in flexible plastic can be surgically implanted on the surface of the brain or under the brain to locate a seizure focus better (14). Grids also have the potential advantage of serving as conduits for electrical stimulation that can be used to map the individual anatomy of eloquent sensory, motor, or language areas of the brain in a person about to undergo seizure surgery (15). Figure 4 shows examples of depth electrodes in place on plain skull X rays. Only a small percentage of people with epilepsy are candidates for this type of invasive recording. One of the challenges of neuroradiology is to develop less invasive techniques for mapping seizure foci and functionally eloquent regions of the brain.

After a clinician has decided, primarily from the clinical history supplemented with the EEG findings, that a patient has epilepsy and has classified the seizure type, the next step is to consider possible causes of the seizure. This entails systematic consideration of the etiologic entities listed in Table 1 above. Routine blood tests are useful to find underlying infectious causes or organ system failures such as renal or hepatic failure. Meningoencephalitis, such as herpes simplex encephalitis, can present with fulminant seizures. Metabolic abnormalities such as hyponatremia, hypocalcemia, hypoglycemia, and hypoxia can all lead to seizures. Drug intoxication with prescription medications such as antihistamines, aminophylline, tricyclics, phenothiazines, certain prescription antibiotics, and amphetaminelike drugs can lead to seizures, as can cocaine or alcohol withdrawal.

Neuroradiologic studies play a key role in the search for the structural cause of seizures. For

Fig 4. Examples of multiple depth electrodes in place on plain skull radiographs. *Arrows* indicate individual electrical contacts on one of the depth wires.

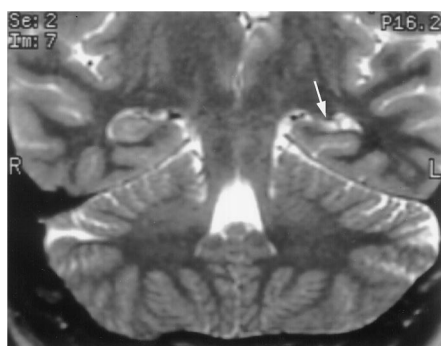
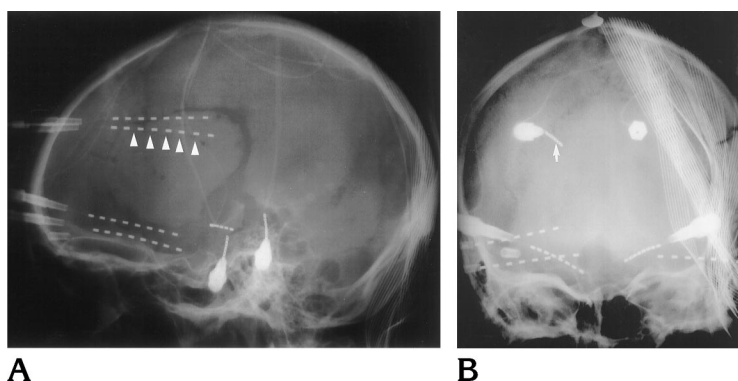


Fig 5. Example of mesial temporal sclerosis on T2-weighted MR (3700/90 [repetition time/effective echo time]) with thin cuts through the hippocampal formations.

practical purposes, a CT scan has almost no role in the evaluation of epilepsy when there are adequate facilities for high-quality MR images. CT might be useful in an emergency setting, or where suspicion is high for subarachnoid hemorrhage or calcified lesions (such as tuberous sclerosis). MR is superior for the detection of low-grade tumors, cavernous malformations, other vascular malformations, dysplasias and migration abnormalities, early abscesses, and mesial temporal sclerosis (Fig 5).

Mesial temporal sclerosis deserves special comment because it is associated with intractable complex partial seizures in most cases. First described by Sommer in 1880, mesial temporal sclerosis, or Ammon's horn sclerosis, involves loss of select cell populations in the hippocampus, with compensatory regrowth of other fiber systems (16). The resultant hippocampus is hyperexcitable. There has been a longstanding argument over whether mesial temporal sclerosis reflects disease that causes seizures, or whether it is an epiphenomenon resulting from severe seizures. Modern view holds that mesial temporal sclerosis can result from but also contribute to an ongoing process of epileptogenesis (17).

Numerous animal studies show that vigorous stimulation of afferents to the hippocampus can produce a picture much like mesial temporal sclerosis (18). In 10% to 25% of cases, mesial temporal sclerosis will at autopsy be found to be bilateral (19). Mesial temporal sclerosis can be visible on MR images with characteristic findings usually best seen in thin (2 to 3 mm) coronal sections. These illustrate atrophy of the hippocampus, enlargement of the adjacent temporal horn of the ventricle, and increased signal on T2-weighted studies (20, 21). Analysis of hippocampal volumes with computer-aided tracing can quantify these differences (22), but visual inspection by experienced neuroradiologists probably suffices (23). A finding of mesial temporal sclerosis in an individual with possible seizures serves to secure the diagnosis of epilepsy, and strongly suggests that that temporal lobe is involved in the epileptic process. It does not, however, rule out significant participation of the other temporal lobe or extratemporal regions of brain in the epilepsy. This point is important for surgical location, because participation of other structures might predict surgical failure.

Treatment

The next clinical step in treatment of epilepsy is initiation of medical therapy. Seizures can have serious consequences such as traumatic injuries, aspiration pneumonias, rhabdomyolysis, cardiac arrhythmias, and, rarely, sudden death. Seizures that persist for more than 30 minutes are known as *status epilepticus*, and in such circumstances brain cell demand hypoxia can result in the loss of neurons. Hippocampal pyramidal cells, cerebellar Purkinje cells, and cortical neurons are particularly vulnerable (24). Diagnosis of a seizure disorder does not

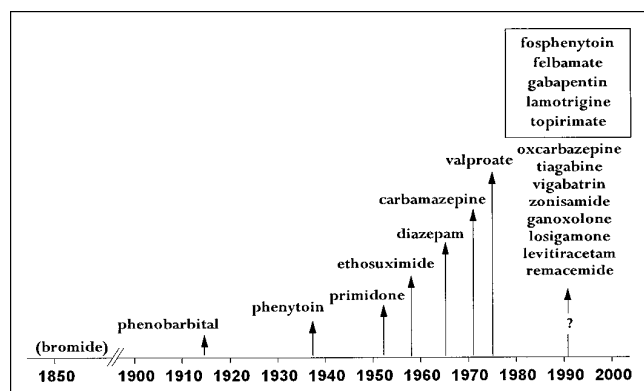


Fig 6. Timeline of approved and anticipated anticonvulsant drug development and release.

necessarily mandate treatment. Recurrence rate after a single idiopathic generalized tonic-clonic seizure is in the 30% to 50% range over several years, and one may decide not to treat unless a second seizure occurs (25). This decision is usually individualized based on a patient's distress over the possibility of another seizure versus antipathy to long-term medication and chronic side effects. Some seizures, such as simple partial seizures, can be sufficiently mild not to require treatment.

Most recurrent seizures will be treated. Figure 6 shows a timeline of antiepileptic medications now in use or in late-stage clinical testing. Details of antiepileptic drug therapy are beyond the scope of this review. Properly controlled comparative studies are few and far between, with that of Mattson et al (26) being the most definitive. For partial seizures, this study showed similar efficacy for carbamazepine (Tegretol), phenytoin (Dilantin), phenobarbital (Luminal), and primidone (Mysoline). A follow-up study (27) showed that valproic acid (Depakene, Depakote) was almost as good as carbamazepine for partial seizures. Clinicians choose seizure medications in large part based on side effect profiles, convenience factors such as daily dosing regimens, cost, and familiarity. Some of the newer medications, particularly gabapentin (Neurontin), lamotrigine (Lamictal), and vigabatrin (Sabril) appear to be better tolerated than some of the older medications (28).

All available seizure medications serve to suppress abnormal epileptiform activity of the brain, but none has yet been documented to prevent the development of the process of epilepsy after a brain injury or in a genetically

predisposed individual. In this sense the term "antiepileptic" medication is really a misnomer. Development of true antiepileptic drugs remains a major target of research.

Psychosocial Issues

A large part of the practical management of epilepsy is dealing with psychosocial issues. Epilepsy significantly decreases quality of life (29). Even when seizures are infrequent, there is ongoing worry about the unpredictable emergence of a seizure at a difficult moment. Chronic antiepileptic medications often produce low-level or even frank, toxic side effects, such as fatigue, concentration and memory problems, depression, blurred vision, nausea, imbalance, weight gain, and a long list of other potential side effects. People with epilepsy also feel stigmatized. There are limits on their ability to work, to drive, and to interact normally with their peers. Children can be limited in school or suffer from peer ridicule and misunderstanding. The incidence of depression is much higher than baseline in one group of people with epilepsy (30). The true goal of therapy for people with epilepsy is not control of seizures, but overall improvement in their quality of life.

Epilepsy Surgery

Medical therapy for epilepsy is satisfactory in approximately two thirds of patients. The remainder can be very impaired by ongoing seizures or toxic medication side effects. Some of these persons are candidates for surgery to ablate the seizure focus. It has been estimated that in the United States between 70 000 and 100 000 people are candidates for epilepsy surgery; the operation is therefore substantially underused (31). Table 4 shows surgeries that have been used to treat epilepsy, pioneered by Penfield, Jasper, Rasmussen, and colleagues in Montreal, the Falconer group in London, Baily, Green, and several other early neurologists and neurosurgeons. These operations include removal of a regional seizure focus, removal of a lobe of the brain, interruption of pathways for seizure spread, corpus callosal resection, and hemispherectomy. The most useful and most commonly performed operation is anterior-mesial partial temporal lobectomy in treatment of unilateral intractable complex partial epilepsy. Surgery can be performed only on one

TABLE 4: Epilepsy surgeries: types and considerations

Surgery	Applicable Cases	Special Considerations
Anterior/medial temporal lobectomy	Intractable partial seizures with or without secondary generalization	Usually in patients with mesial temporal sclerosis (the most common cause of intractable partial complex seizures)
Multiple subpial cortical transection	Intractable partial seizures originating from areas of eloquent cortex	Leaves vertically oriented input and output tracts intact; useful for limiting lateral spread of seizures
Focal cortical resection	Partial seizures with or without secondary generalization	Requires focal cortical lesion identified with either imaging or EEG mapping
Corpus callosum resection	Generalized atonic (astatic) seizures or multifocal seizures with secondary generalization	Useful in preventing secondary generalization of seizures via spread to opposite hemisphere; used most commonly in patients with severe atonic (astatic) seizures in which head trauma is frequent complication because of abrupt nature of fall
Hemispherectomy	Severe multifocal unilateral seizures or patients with Rasmussen encephalitis	Used primarily for control of seizures in patients with Rasmussen encephalitis (a progressive unilateral destructive encephalitis in children)

TABLE 5: Methods to locate seizure onset

Surface EEG
Invasive EEG
Depth wires
Grid implantation
Corticography at time of resection
Standard imaging
MR with or without special protocols
Thin-section mesial temporal images
Fluid-attenuated inversion-recovery, diffusion
Angiogram in appropriate patients
Nuclear medicine
Ictal and/or interictal single-photon emission CT
Interictal positron emission tomography
Other
Functional MR (blood oxygen level-dependent)
MR spectroscopy
Magnetoencephalography

side, because bilateral temporal lobectomy produces the Kluver-Bucy syndrome, including severe and lasting memory registration impairments. Presurgical evaluation must locate a seizure focus in either the left or the right temporal lobe, but not both, in order for surgery to be a good option. Distinction must also be made between the more common mesial temporal epilepsy arising in hippocampus, amygdala, or perihippocampal gyrus, versus the less common temporal neocortical seizure focus. Table 5 lists methods commonly used to locate a seizure focus. Clinical semiology, or careful observation of behavior during a seizure, is part of every preoperative evaluation, but unfortunately turns out to be unhelpful in most cases. There is no pathognomonic physical sign to indicate whether seizures come from the left or the right temporal region. Localizing signs such as rhythmic twitching of face or limb

or pointing to the contralateral motor cortex occur later in complex partial seizures, when spread might have become contralateral. Head and eye turning and various types of posturing correlate only approximately with side of seizure onset. Speech arrest early in a seizure can be a nonspecific part of general arrest of activities, but sometimes points to a seizure focus near the speech areas of the dominant hemisphere.

EEG interictal spikes, as discussed above, are predictive markers of sites of epilepsy, but they are not as reliable as ictal onset from video-EEG monitoring during a seizure. Every modern epilepsy surgery center would obtain an MR study of patients who are possible surgical candidates for epilepsy. MR would be part of a search for underlying structural causes and for detection of mesial temporal sclerosis. The role of fluid-attenuated inversion-recovery and other special pulse sequences remains to be determined. Neuropsychological testing is useful to indicate lateralized deficits with language, word memory, picture memory, block design, frontal lobe executive function, or other deficits that might point to a focal area of cerebral disturbance (32). Neuropsychological testing also can show the psychological characteristics of the patients, which might be important for detection of depression or epilepsy-associated psychosis or adjustment disorders.

Core evaluation of presurgical patients at almost all centers includes clinical semiology, interictal EEG, and MR imaging. Most centers also perform ictal video-EEG recording, but an argument can be made that with clear-cut mesial temporal sclerosis and interictal spikes

most patients will do well with surgery. Unfortunately, a few of these patients have bilateral seizure onset, which would not be detected without ictal recording. Further evaluation is highly variable among different epilepsy centers. Based on the experience of the University of California Los Angeles epilepsy center, many programs, including ours, divide patients into noninvasive and invasive candidates. An ideal candidate for surgery with a noninvasive workup has lateralized interictal spikes, ictal seizure onset to one temporal lobe, and mesial temporal sclerosis on that same side. Neuropsychological test dysfunction should also lateralize to the side with mesial sclerosis. Such candidates have over an 70% chance of a surgical cure with anterior mesial temporal lobectomy. If there is discord or absence of mesial temporal sclerosis on MR, then additional testing is of value, but the patient is less likely to be cured by surgery (33). This additional testing can include invasive depth wires, which are fairly definitive for location of seizures to mesial temporal structures if that is where they originate. Wires can be placed stereotactically by a variety of approaches, and typically are inserted into the amygdala, hippocampus, superior frontal/supplementary motor area, and orbitofrontal cortex.

Following the lead studies of the UCLA group (34), positron emission tomography (PET) has become part of the presurgical evaluation in many epilepsy centers. The central finding is that the temporal lobe is hypometabolic for uptake of glucose on the side of the seizure focus during the interictal period (34, 35). The region of hypometabolism can be both medial and lateral, and commonly exceeds the size of tissue that needs to be removed for cure of seizures. PET can be useful in eliminating the need for invasive studies. In one series of 37 patients with intractable complex partial epilepsy who had concordance of data between noninvasive EEG testing and PET scans, depth wire encephalography added no new important information in any case (36). The usual radioisotope for PET studies is fludeoxyglucose F 18, which is taken up in proportion to the rate of glucose metabolism in neurons and trapped because it cannot be metabolized by phosphokinase. The radioactive decay emits a positron that travels a short distance through brain tissue and decays to two photons with opposite directions. Scintillation counters detect the simultaneous arrival

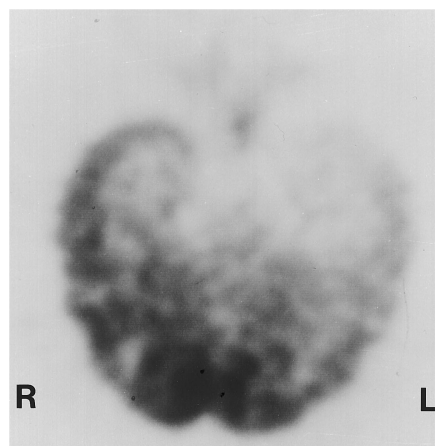


Fig 7. Hypometabolic interictal PET scan with fludeoxyglucose shows marked left temporal hypometabolism.

of two photons, and use algorithms to mark the likely place of origin of the positron. Figure 7 shows a hypometabolic area in the left temporal lobe in a patient with left temporal epilepsy. If a complex partial seizure occurs during the early uptake phase of fludeoxyglucose, then the involved structures are hypermetabolic. With the aid of expert radiochemists, ligands other than fludeoxyglucose can be used for PET scanning. Oxygen 15 is useful for marking cerebral activity over spans of several minutes because it has a short radioactive half-life. Analogues of neurotransmitters can be used to mark numbers of available neurotransmitter receptor binding sites in relation to seizure foci. Neuroreceptor studies have indicated that opiate-mu receptors are increased in neocortex adjacent to a mesial temporal lobe seizure focus (37), possibly as a homeostatic mechanism to attempt to contain the seizure spread. Benzodiazepine receptors, labeled by flumazenil, are decreased in mesial temporal structures near a seizure focus, and cholinergic markers are similarly decreased (38). Neuroreceptor mapping is not in general clinical use, but might give some supplementary information in cases where fludeoxyglucose PET scans are negative. The primary value of neuroreceptor mapping is insight into the neurochemical mechanisms of chronic epilepsy in humans.

Use of MR spectroscopy to elucidate problems in epilepsy is relatively new. MR spectroscopy can measure pH, concentrations of high-energy phosphates, and proton spectra in defined volumes of brain tissue. Interictal increased pH in the temporal lobe ipsilateral to the seizure onset has been demonstrated in sev-

eral studies (39). Reduced levels of *N*-acetyl-aspartate have also been identified in the temporal lobes ipsilateral to the seizure focus (40); however, in vitro studies of surgically extricated tissue from seizure foci have not confirmed this finding (41). MR spectroscopy, therefore, is promising for locating seizure focus, but at present remains investigational.

The more information obtained from various methods, the more secure the clinician can be in locating a seizure focus or in determining that the epilepsy is in fact multifocal and not amenable to surgical cure. Balanced against this increasing diagnostic certainty is economic factors, since these tests are costly. Staged evaluations should be performed, with costly studies reserved for potential surgical candidates whose focus location is not clear from clinical semiology, EEG, and MR. The marginal value of various tests remains to be determined, and provides a moving target as new tests and better accuracy of old tests changes on a frequent basis.

Functional Location of Eloquent Regions of Brain

The goal of the surgeon is to separate the "good brain" from the "bad brain." The bad brain is presumptively that which is intermingled with the seizure focus. Good brain is that which must be left intact or risk significant postoperative deficit. Motor, sensory, and speech areas might be at risk in extratemporal surgery, but language function is primarily at risk with temporal surgery.

The first issue is whether temporal lobectomy is to be on the speech-dominant side or not. More than 95% of right-handed subjects have speech lateralized to the left hemisphere. Left-handers, particularly those with a family history of left-handedness and no forced change in handedness in their youth, usually have speech in the right hemisphere, but might have mixed speech dominance or ipsilateral speech dominance. Because surgical resection can be more aggressive in the nondominant hemisphere, without fear of encroaching on Wernicke's receptive speech area, it is important to lateralize speech before seizure surgery. This is presently done with the Wada intracarotid amobarbital test. Via standard angiographic techniques, a catheter is placed at the cervical II level of the internal carotid artery, and sodium amobarbital

is injected over a few seconds. The barbiturate transfers in a first pass into brain tissue and essentially "anesthetizes" the internal carotid distribution. The effect of the drug can be verified by concurrent EEG testing (which also controls for confounding seizures during the testing) and observation of a contralateral hemiparesis. Doses ranging from 100 to 300 mg of amobarbital are used in different centers. During the time of hemiparesis, receptive and expressive speech are tested. Aphasia is taken as evidence that that side is dominant for language or at least participates with the other side in language functions.

In the early 1960s, Brenda Milner at the Montreal Neurological Institute extended the Wada test to evaluation of modality-specific memory as well as language (42). This was done because a few patients experienced debilitating amnesia after resection of one temporal lobe, because the remaining temporal lobe could not support memory. The Wada test for memory is empirical. Much of the hippocampal anatomy is not perfused with internal carotid injection (43), but isolation of mesial temporal structures, and effects on neocortical temporal memory centers appear to be sufficient after internal carotid injections to make some reliable predictions about postoperative memory function. Selective injections of smaller vessels such as the posterior cerebral artery (44) and anterior choroïdal artery (45) have been useful, but are infrequently used because of the risk of stroke with instrumentation of these smaller vessels. The central positive finding in a Wada memory test is global amnesia for all modalities of memory. Such an outcome suggests that the patient is at very high risk for postoperative severe memory deficits. Expected during the Wada test are modality-specific memory problems such as word memory difficulty for the dominant hemisphere and shape, picture, or face memory problems for the nondominant hemisphere. Passing a Wada test does not mean that there will be no postoperative memory deficits, only that the memory deficits are likely to be modality specific and rarely catastrophic. Hermann et al (46) have shown that the presence of mesial temporal sclerosis in resected tissue is a good predictor of minimal postoperative memory deficit after anterior temporal lobectomy. This is probably because little functional tissue is lost since the resected hippocampus is dysfunctional before surgery.

The Wada test also can be used to predict postoperative success rates for seizure control. Injection of the nonepileptic side should result in a memory deficit, since the sclerotic hippocampus often cannot support memory on its own. Therefore the presence of a memory deficit after injection of the "healthy" side is a reassuring observation (47).

Interpretation of Wada testing is difficult because virtually every epilepsy center has its own protocol and methods for applying the findings. Randomized control studies of the value of the tests are lacking. Methodological issues and controversies are reviewed in detail in an article by Rausch et al (48).

The Wada intracarotid amobarbital test is of course of particular interest to neuroradiologists, since it is in large part a neuroradiologic study. Alternative, less-invasive methods are now available for lateralization of speech. These include PET with oxygen 15 or other isotopes during speech and nonspeech tasks and functional MR during verbal tasks and transcranial magnetic stimulation to disrupt speech on the speech-dominant side (49). Unfortunately, no substitute is yet available for the memory portion of the Wada test. The study therefore still has a role in the preoperative evaluation of seizure patients.

If a decision is made to operate on a speech-dominant side, then the epilepsy team has a choice between standard resection of a fixed amount of tissue or tailored resection based on location of the seizure focus and precise location of Wernicke's speech area. For usual anterior mesial temporal lobe epilepsy, individualized mapping probably does not add a great deal to outcome and vastly increases the expense and procedural risk to the patient. The reverse might be the case with posterior seizure foci in the temporal lobe or in other cases in which there is reason to believe that the focus is near speech areas. Mapping procedures are also used in extratemporal epilepsy where the extent of the seizure focus is less clear than in temporal lobe epilepsy and sensory motor areas might be near the focus.

Mapping of eloquent areas of cortex can be done during surgery with the patient under local anesthesia, or it can be done in a two-stage procedure with implantation of electrodes on the surface of the brain, followed by a second-stage removal of electrodes and resection. Figure 8 portrays a grid on the surface of the brain

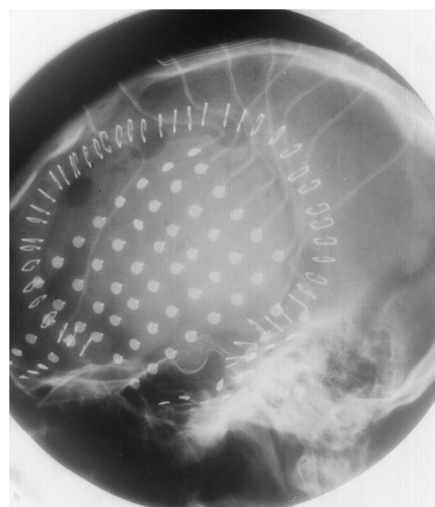


Fig 8. Grid on surface of brain for EEG seizure mapping and for mapping of eloquent cortex with electrical stimulation as seen on plain lateral skull radiograph.

that can be used for recording and stimulation. The advantage of the grid over intraoperative mapping is much greater detail over time of functional areas of brain and less risk of an untestable patient because of anxiety, anesthesia reaction, or a seizure during surgery. The grid also can record ictal events unlikely to occur during surgery. The grid, however, has the disadvantages of extra expense, introduction of an additional craniotomy, and a complication rate of its own. Approximately 4% of patients undergoing grids have serious infections, and a few have major cerebral edema and microinfarcts because of the grid (50).

There is a major need for neuroradiologic studies to map eloquent regions of the brain. Functional MR is a new technique that shows promise in this regard. Traditionally, $H_2^{15}O$ PET has been used to map eloquent cerebral cortex. Recently, functional MR that makes use of changes in the paramagnetic effects of deoxyhemoglobin has evolved as a new technique for cortical mapping. The blood oxygen level-dependent (BOLD) technique relies on the decrease in paramagnetic T2 signal loss that occurs with increasing blood oxygenation. The paramagnetic effects of deoxygenated hemoglobin result in regional decreases in bulk T2 value. By contrast, oxygenated hemoglobin has minimal paramagnetic effect and therefore does not result in T2 signal loss. Areas of cortical brain activation receive increased cortical perfusion and secondarily increased blood oxygenation. The associated local decrease in para-

magnetic effects results in a regional increase in signal on T2 weighted images. Therefore, the BOLD technique defines regions of cortical activation by measuring the increase in MR signal on T2 weighted images that occur in conjunction with increased blood oxygenation in areas of cortical activation.

The signal increase of the BOLD technique is subtle and statistical image generation is used to generate high quality maps of cortical function. Activation of the visual cortex at 1.5 T results in only a 1% to 5% increase in regional signal intensity (51). Multiple rapid T2-weighted gradient-echo or echo planar images are therefore obtained with and without the patient performing a cortical stimulation paradigm. The resulting two image sets are then compared on a pixel-by-pixel basis with either a paired *t* test or an analysis of variance (ANOVA) test to generate an image of cortical activation. The resulting statistical image is then typically overlaid on a conventional anatomic MR image for presentation.

Investigators are currently using the BOLD technique to locate the visual and motor cortex, show brain plasticity, show the relationship of surgical lesions to eloquent cortex, and locate Broca's area. Jackson et al (52) have reported a patient with Rasmussen encephalitis who while sedated in the magnet was observed to show the patient's typical ictal activity without significant head motion. BOLD images were obtained and increased cortical activation (seizure activity) was located in the left frontotemporal region. Functional MR techniques hold promise as a new cost-effective mode in the physiologic assessment of the epileptic patient.

Conclusion

Epilepsy is a highly prevalent and serious neurologic disorder. Diagnosis and treatment remain problematic, despite an array of medical and surgical treatment options. Neuroradiology has made a major contribution to diagnosis of epilepsy by showing underlying lesions, identifying sclerotic hippocampus, and locating regions of hypometabolism and spectroscopically detected chemical changes. The Wada intracarotid amobarbital test is the mainstay of the presurgical workup to locate speech and memory. Functional MR might someday replace or supplement more invasive methods for mapping eloquent areas of brain in relation to the

seizure focus. Epilepsy treatment is now done by team approach and the neuroradiologist is becoming an increasingly important member of this team.

References

1. Hauser WA. Incidence and prevalence. In: Hauser WA, Hesdorffer DC, eds. *Epilepsy: Frequency, Causes, and Consequences*. New York, NY: Demos Publications; 1990:1-51
2. Fisher RS. Animal models of the epilepsies. *Brain Res Rev* 1989; 14:245-278
3. Nelson KB, Ellenberg JH. Predisposing and causative factors in childhood epilepsy. *Epilepsia* 1987;28:S16-S24
4. Hauser WA, Kurland LT. The epidemiology of epilepsy in Rochester, MN, 1935 through 1967. *Epilepsia* 1975;16:1-66
5. Commission on Classification and Terminology of the International League Against Epilepsy. Proposal for the classification of epilepsy and epileptic syndromes. *Epilepsia* 1989;30:389-399
6. Dreifuss FE. Classification of epileptic seizures and the epilepsies. *Pediatr Clin North Am* 1989;36:265-279
7. Penfield W, Jasper H. *Epilepsy and the Functional Anatomy of the Human Brain*. Boston, Mass: Little Brown & Co; 1954
8. Kobayashi K, Ohtsuka Y, Oka E, Ohtahara S. Primary and secondary bilateral synchrony in epilepsy: differentiation by estimation of interhemispheric small time differences during short spike-wave activity. *Electroencephalogr Clin Neurophysiol* 1992;83:93-103
9. Fisher RS. *Imitators of Epilepsy*. New York, NY: Demos; 1994
10. Salinsky M, Kanter R, Dasheiff RM. Effectiveness of multiple EEGs in supporting the diagnosis of epilepsy: an operational curve. *Epilepsia* 1987;28:331-334
11. Blum DE. Prevalence of bilateral seizures and implications for electroencephalographic telemetry monitoring. *Electroencephalogr Clin Neurophysiol* 1994;91:329-336
12. Sutherling WW, Levesque MF, Crandall PH, Barth DS. Localization of partial epilepsy using magnetic and electric measurements. *Epilepsia* 1991;32:S29-S40
13. Buser P, Bancaud J, Talairach J. Depth recordings in man in temporal lobe epilepsy. In: Brazier MAB, ed. *Epilepsy: Its Phenomena in Man*. New York, NY: Academic Press Inc; 1973:67-97
14. Wyler AR, Walker G, Richley ET, Herman BP. Chronic subdural strip electrode recordings for difficult epileptic problems. *Epilepsia* 1988;1:71-78
15. Uematsu S, Lesser R, Fisher R, et al. Resection of the epileptogenic area in critical cortex with the aid of a subdural electrode grid. *Stereotact Funct Neurosurg* 1990;54:34-45
16. Wyllie E. *The Treatment of Epilepsy: Principles and Practice*. Malvern, Pa: Lea & Febiger; 1993:1074
17. Spencer SS. Selection of candidates. In: Wyllie E, ed. *The Treatment of Epilepsy: Principles and Practice*. Malvern, Pa: Lea & Febiger; 1993:1063
18. Sloviter RS, Damiano BP. Sustained electrical stimulation of the perforant path duplicates kainate-induced electrophysiological effects and hippocampal damage in rats. *Neurosci Lett* 1981;24: 279-284
19. Margerison JH, Corsellis JAN. Epilepsy and the temporal lobes: a clinical, electroencephalographic and neuropathological study of the brain in epilepsy, with particular reference to the temporal lobes. *Brain* 1966;89:499-530
20. Kuzniecky R, de la Sayette V, Ethier R, et al. Magnetic resonance imaging in temporal lobe epilepsy: pathological correlations. *Ann Neurol* 1987;22:341-347

21. Berkovic SF, Andermann F, Olivier A, et al. Hippocampal sclerosis in temporal lobe epilepsy demonstrated by magnetic resonance imaging. *Ann Neurol* 1991;29:175-182
22. Cascino G, Jack CR Jr, Parisi JE, et al. Magnetic resonance imaging-based volume studies in temporal lobe epilepsy: pathological correlations. *Ann Neurol* 1991;30:31-36
23. Jackson GD, Berkovic SF, Tress BM, Kalnins RM, Fabinyi GC, Bladin PF. Hippocampal sclerosis can be reliably detected by magnetic resonance imaging. *Neurology* 1990;40:1869-1875
24. Meldrum BS, Brierley JB. Prolonged epileptic seizures in primates: ischemic cell change and its relation to ictal physiological events. *Arch Neurol* 1973;28:10-17
25. Berg AT, Shinnar S. The risk of seizure recurrence following a first unprovoked seizure: a quantitative review. *Neurology* 1991;41:965-972
26. Mattson RH, Cramer JA, Collins JF, et al. Comparison of carbamazepine, phenobarbital, phenytoin, and primidone in partial and secondarily generalized tonic-clonic seizures. *N Engl J Med* 1985;313:145-151
27. Mattson R, Cramer JA, Collins JF. A comparison of valproate with carbamazepine for the treatment of complex partial seizures and secondarily generalized tonic-clonic seizures in adults. *N Engl J Med* 1992;327:765-771
28. Fisher RS. Emerging antiepileptic drugs. *Neurology* 1993;43:S12-S20
29. Santilli N, Kessler BL, Schmidt WT. Quality of life in epilepsy: perspectives of patients. In: Trimble MR, Dodson WE, ed. *Epilepsy and Quality of Life*. New York, NY: Raven Press; 1994:1-18
30. Dodrill CB, Batzel LW. Interictal behavioral features of patients with epilepsy. *Epilepsia* 1986;27:S64-S76
31. Engel J Jr, Shewmon DA. Who should be considered a surgical candidate. In: Engel J Jr, ed. *Surgical Treatment of the Epilepsies*. 2nd ed. New York, NY: Raven Press; 1993:23-34
32. Jones-Gotman M. Neuropsychological techniques in the identification of epileptic foci. In: Engel J Jr, ed. *Surgical Treatment of the Epilepsies*. 2nd ed. New York, NY: Raven Press; 1993:87-94
33. Engel J Jr, Van Ness PC, Rasmussen TB, Ojemann LM. Outcome with respect to epileptic seizures. In: Engel J Jr, ed. *Surgical Treatment of the Epilepsies*. 2nd ed. New York, NY: Raven Press; 1993:609-622
34. Engel J Jr, Kuhl DE, Phelps ME. Patterns of human local cerebral glucose metabolism during epileptic seizures. *Science* 1982;218:64-66
35. Therapeutics and technology assessment subcommittee of the American Academy of Neurology. Assessment: positron emission tomography. *Neurology* 1991;41:163-167
36. Engel J Jr, Henry TR, Risinger MW, et al. Presurgical evaluation for partial epilepsy: relative contributions of chronic depth-electrode recordings versus FDG-PET and scalp-sphenoidal ictal EEG. *Neurology* 1990;40:1670-1677
37. Frost JJ, Mayberg HS, Fisher RS, et al. Mu-opiate receptors measured by positron emission tomography are increased in temporal lobe epilepsy. *Ann Neurol* 1988;23:231-237
38. Savic I, Persson A, Roland P, Pauli S. In-vivo demonstration of reduced benzodiazepine receptor binding in epileptic foci. *Lancet* 1988;2:863-866
39. Laxer KD, Hubsch B, Sappey-Marineier D, Weiner MW. Increased pH and inorganic phosphate in temporal seizure foci demonstrated by ³¹P MRS. *Epilepsia* 1992;33:618-623
40. Hugg JW, Laxer KD, Matson GB, Maudsley AA, Weiner MW. Neuron loss localizes human temporal lobe epilepsy by in vivo proton magnetic resonance spectroscopic imaging. *Ann Neurol* 1993;34:788-794
41. Peeling J, Sutherland G. ¹H Magnetic resonance spectroscopy of extracts of human epileptic neocortex and hippocampus. *Neurology* 1993;43:589-594
42. Milner B, Branch C, Rasmussen T. Study of short-term memory after intracarotid injection of sodium amytal. *Trans Am Neurol Assoc* 1987:224-226
43. Jeffery PJ, Monsein LH, Szabo Z, et al. Mapping the distribution of amobarbital sodium in the intracarotid Wada test by use of Tc-99m HMPAO with SPECT. *Radiology* 1991;178:847-850
44. Jack CR, Nichols DA, Sharbrough FW, Marsh WR, Petersen RC. Selective posterior cerebral artery amytal test for evaluating memory function before surgery for temporal lobe seizure. *Radiology* 1988;168:787-793
45. Wieser HG, Valavanis A, Roos A, Isler P, Renella RR. "Selective" and "superselective" temporal lobe amytal tests. In: *Neuroradiological, Neuroanatomical, and Electrical Data Advances in Epileptology*. New York, NY: Raven Press; 1989;17:20-27
46. Hermann BP, Seidenberg M, Dohan FC Jr, et al. Reports by patients and their families of memory change after left anterior lobectomy: relationship to degree of hippocampal sclerosis. *Neurosurgery* 1995;36:39-44
47. Rausch R, Babb TL, Engel J Jr, Crandall PH. Memory following intracarotid amobarbital injection contralateral to hippocampal damage. *Arch Neurol* 1989;46:783-788
48. Rausch R, Silfvenius H, Wieser HG, Dodrill CB, Meador KJ, Jones-Gotman M. Intraarterial amobarbital procedures. In: Engel J Jr, ed. *Surgical Treatment of the Epilepsies*. 2nd ed. New York, NY: Raven Press; 1993:341-357
49. Pascual-Leone A, Gates JR, Dhuna A. Induction of speech arrest and counting errors with rapid-rate transcranial magnetic stimulation. *Neurology* 1991;41:697-702
50. Van Buren JM. Complications of surgical procedures in the diagnosis and treatment of epilepsy. In: Engel J Jr, ed. *Surgical Treatment of the Epilepsies*. New York, NY: Raven Press; 1987:465-475
51. Turner R, Jezzard P, Wen H, et al. Functional mapping of the human visual cortex at 4 and 1.5 Tesla using deoxygenation contrast EPI. *Magn Reson Med* 1993;29:277-279
52. Jackson GD, Connelly A, Cross JH, et al. Functional magnetic resonance imaging of focal seizures. *Neurology* 1994;44:850-856