

Are your **MRI contrast agents** cost-effective?

Learn more about generic **Gadolinium-Based Contrast Agents**.



FRESENIUS
KABI

caring for life

AJNR

Congenital hypothyroidism: assessment with ultrasound.

S Takashima, N Nomura, H Tanaka, Y Itoh, K Miki and T Harada

AJNR Am J Neuroradiol 1995, 16 (5) 1117-1123

<http://www.ajnr.org/content/16/5/1117>

This information is current as
of June 29, 2024.

Congenital Hypothyroidism: Assessment with Ultrasound

Shodayu Takashima, Naoko Nomura, Hisashi Tanaka, Yasushi Itoh, Kazunori Miki, and Tokuzo Harada

PURPOSE: To determine the clinical utility of cervical ultrasound in patients suspected of having congenital hypothyroidism. **METHODS:** Thirty-seven patients with suspected congenital hypothyroidism underwent ultrasound and scintigraphic evaluation of the thyroid anatomy, morphology, and function. The ultrasound findings and laboratory data were compared with the standard-of-reference scintigraphic findings and laboratory data for diagnosing specific causes in those patients, and prognosis was correlated with the ultrasound findings. **RESULTS:** Ultrasound was not reliable for detecting ectopia ($n = 8$) or differentiating ectopia from aplasia ($n = 1$). Ultrasound showed ectopia in six (four in the mouth floor and two in the tongue base) of eight cases (75% sensitivity). Ultrasound did not show one ectopia in the floor of mouth because its echogenicity was similar to that of surrounding tissues. A second ectopia, in the hypopharynx, was missed because of hindrance of the laryngeal air. Radioactive iodine uptake and scintigraphy was required for the patients with enlarged glands in the normal place to differentiate dysmorphogenesis from other categories. Specific causes were diagnosed correctly with ultrasound findings and laboratory data alone in all of the 20 patients who had hemi- or aplasia or small or normal-size glands in the normal location. Incidences of heterogeneity and hypoechogenicity of the thyroid gland in patients with prolonged clinical course (whose replacement therapy or follow-up extended for more than 1 year) were significantly higher than those in patients with short clinical course. **CONCLUSION:** Ultrasound can obviate the need for scintigraphy in more than half (54%) of patients with possible congenital hypothyroidism. Ultrasound has a potential to predict prognosis of these patients.

Index Terms: Thyroid gland, ultrasound; Thyroid gland, hypothyroidism

AJNR Am J Neuroradiol 16:1117-1123, May 1995

Mass screening for congenital hypothyroidism, using blood samples collected on filter paper, has been performed in Japan since 1979. In our country infants with a filter paper thyrotropin level of more than $10 \mu\text{U}/\text{mL}$ are considered at risk and recalled immediately for a second test. With this screening method, congenital hypothyroidism is discovered in 1 of 5500 newborns in our country (1). Early discovery and prompt initiation of replacement therapy with levothyroxine sodium are crucial to prevent mental retardation (1). Scintigra-

phy combined with biochemical data has been considered indispensable to establish a specific etiologic diagnosis of primary congenital hypothyroidism (2-4). Although the clinical importance of scintigraphy in this disorder is well documented (2-4), there are only a few reports in which ultrasound and its role in this entity are studied (4-6).

We report ultrasound findings of the thyroid gland in infants suspected of having congenital hypothyroidism. Its clinical efficacy in this condition is studied.

Subjects and Methods

This study group consists of 37 patients (19 boys and 18 girls) who were referred to Osaka University Hospital because of elevated concentrations of serum thyrotropin or decreased serum thyroxine levels at neonatal mass screening from October 1983 to February 1993. All of the patients underwent thyroid sonography and scintigraphy before thyroid replacement therapy. Mean ages at the time of ultrasound and scintigraphy were 4.5 weeks (range, 1 to

Received July 27, 1994; accepted after revision November 21.

From the Department of Radiology, Osaka Teishin Hospital (S.T.) and the Departments of Radiology (N.N., H.T., Y.I.) and Pediatrics (K.M., T.H.), Osaka University Medical School, Osaka, Japan.

Address reprint requests to Shodayu Takashima, MD, Department of Radiology, Osaka Teishin Hospital, 2-6-40 Karasugatsuji, Tennohji-ku, Osaka 543, Japan.

AJNR 16:1117-1123, May 1995 0195-6108/95/1605-1117

© American Society of Neuroradiology

TABLE 1: Clinical diagnoses, chemical data, and iodine scintigraphy findings

Clinical diagnosis	Chemical Data		Iodine-123 Scintigraphy		
	Thyrotropin Level, $\mu\text{U/mL}$, Mean (Range)	Cases of Low Thyroxine	Radioactive iodine uptake, %		Cases of Positive Washout Test
			Cases	Mean (Range)	
Aplasia (n = 1)	496	1	1
Hemiaplasia (n = 3)	145 (17-257)	2
Ectopia (n = 8)	262 (80-788)	6	4	26 (13-36)	2/2
Dyshormonogenesis (n = 2)	61 (39-82)	2	2	44 (44-46)	2/2
Transient elevated thyrotropin (n = 6)	23 (15-40)	0	1	19	...
Transient hypothyroidism (n = 6)	64 (13-160)	6	5	35 (23-58)	2/3
Persistent elevated thyrotropin (n = 10)	28 (11-52)	0	9	22 (12-30)	0/7
Thyrotropin-releasing hormone deficiency (n = 1)	8.9	1	1	7.7	...

Note.—The normal range of radioactive iodine uptake was 10% to 35%. The normal range of thyrotropin levels was 0.69 $\mu\text{U/ml}$ to 9.76 $\mu\text{U/ml}$.

10 weeks) and 5.1 weeks (range, 1 to 11 weeks), respectively.

Final diagnoses of the 37 patients made based on the findings of chemical laboratory data and scintigraphic findings are summarized in Table 1. In cases of discrepancy between ultrasound and scintigraphy, scintigraphy was used as the standard of reference. Transient elevated thyrotropin was defined as elevated thyrotropin levels and normal thyroid hormone levels in a newborn with spontaneous recovery of thyrotropin levels within 1 year after birth (7). Transient hypothyroidism was defined as high thyrotropin and low thyroxine in a newborn with spontaneous recovery within 1 year (1). Persistent (sustained) elevated thyrotropin was defined as high thyrotropin that endures more than 1 year after birth, but thyroxine levels remain within normal limits (8).

Sonography of the entire neck was performed prospectively with the patients in a supine position, using a real-time mechanical sector scanner with a 7.5- or a 10-MHz transducer (SSD-125; Aloka, Tokyo, Japan) and a real-time sector scanner (RT-3000, Yokogawa, Tokyo, Japan) with a 5-MHz probe. At ultrasound studies, special attention was given to the presence or absence of the thyroid gland and the position of the gland. The gland in the

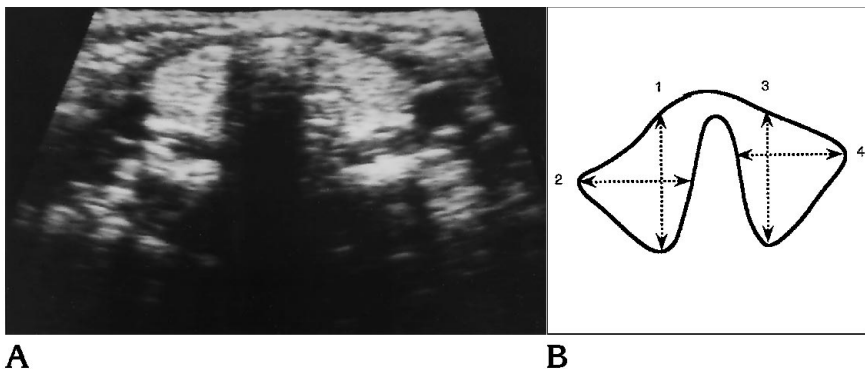
normal location was evaluated for its size and shape (normal or hemiaplasia), echotextures (homogeneous or heterogeneous), and echogenicity (normal or hypoechoic). Fine parenchyma without nodules or cysts was defined as homogeneous echotextures and coarsened parenchyma without nodules or cysts as heterogeneous echotextures. Thyroid glands that had equal or less echogenicity than that of the adjacent sternocleidomastoid muscle were classified as hypoechoic. Echogenicity of the ectopic glands was compared with the surrounding tissue. As indicated in Figure 1, the maximum thickness and the maximum width of the bilateral lobes of the thyroid gland in the normal location were measured on transverse ultrasound images, and the sum of the thickness and sum of the width were calculated in each patient (6). To afford baseline standards of ultrasound morphology and size, ultrasound was also performed in 12 healthy control subjects (mean age, 5.3 weeks; range, 3 to 8 weeks) who had no thyroid disease and showed normal growth. Statistical evaluations were made with Student's *t* tests for unpaired data or χ^2 tests with Yate's correction. $P < .05$ was considered to indicate significance.

Thyroid scintigraphy with either sodium pertechnetate Tc 99m (n = 14) or iodine-123 (n = 23) was performed

Fig 1. Normal thyroid sonogram and method of measurement of thyroid gland size.

A, Transverse ultrasound scan obtained in a healthy control subject shows a thyroid gland of homogeneous parenchyma (width, 18 mm; thickness, 16 mm).

B, Method of measurement of thyroid dimensions (width, 2 + 4; thickness, 1 + 3).



using a gamma camera equipped with a pinhole collimator. Radioactive iodine uptake values at 3 hours were measured in 22 of the 23 patients, and a perchlorate washout test was performed in 14 of these 22 patients (Table 1). The normal range of radioactive iodine uptake at 3 hours in our hospital was 10% to 35% (8). Radioactive iodine uptake values with a decrease of 10% at 2 hours after administration of sodium perchlorate were considered positive for the perchlorate washout test. Scintigraphic findings were read by two radiologists blinded to the sonographic findings, and the final results were made based on the consensus of the two radiologists. Then, the ultrasound findings and laboratory data were compared with the scintigraphic findings and laboratory data for diagnosing specific causes of suspected congenital hypothyroidism, and the clinical value of ultrasound in patients with this disorder was assessed.

Results

Location of the Thyroid Gland with Ultrasound and Scintigraphy

With scintigraphy, a thyroid gland was demonstrated in the normal anatomic location in 28 patients (25 with a normal shape and 3 with hemi- and aplasia) and in ectopic places in 8 (5 in the mouth floor, 2 in the tongue base, and 1 in the hypopharynx), and no thyroid tissue was detected in 1 patient (Table 2). Sonography detected 6 (4 in the mouth floor and 2 in the tongue base) of these 8 ectopias. Of the 4 glands located in the mouth floor, 3 were surrounded by soft tissues, and 1 was between both of the anterior bellies of the digastric muscle; the former 3 appeared hypoechoic ($n = 2$) or cystic ($n = 1$) and the latter 1 hyperechoic to the surrounding muscle but hypoechoic to the nearby soft tissues. Two ectopic glands in the

TABLE 2: Location of thyroid glands with scintigraphy and sonography ($n = 37$)

Scintigraphy	Sonography
Normal place, 25	Normal place, 25
Ectopia, 8	Ectopia, 6*
	Nondetectable, 2†
Hemi- and aplasia, 3	Hemi- and aplasia, 3
	Nondetectable, 1

* Four in the mouth floor and two tongue base.

† One in the mouth floor and one hypopharynx.

tongue base appeared hypoechoic to the residual tongue (Fig 2). One ectopia in the mouth floor and 1 in the hypopharynx were missed with ultrasound. In the former, a repeat ultrasound performed after knowing the location of the ectopia that was indicated with scintigraphy failed to show it presumably because of its similar echogenicity to the surrounding tissues. Thus, ultrasound detection sensitivity, specificity, accuracy, and positive and negative predictive values for ectopia were 75% (6 of 8), 100% (29 of 29), 95% (35 of 37), 100% (6 of 6), and 94% (29 of 31), respectively.

Diagnosis with Ultrasound Findings and Laboratory Data versus Diagnosis with Scintigraphic Findings and Laboratory Data

Thyroid parenchyma was homogeneous and more echogenic than the adjacent sternocleidomastoid muscle in all of the 12 healthy control subjects (Fig 1). Mean width and thickness of the thyroid gland measured on ultrasound images were 17 mm with 1 SD of 2 mm (range, 16 to 20 mm) and 16 mm with 1 SD of 1 mm (range, 14 to 18 mm), respectively (Fig 3).

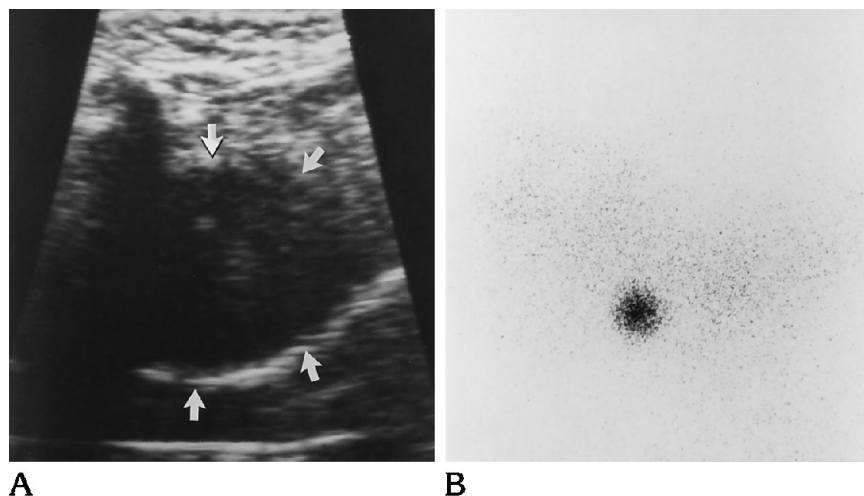


Fig 2. Case of ectopia.

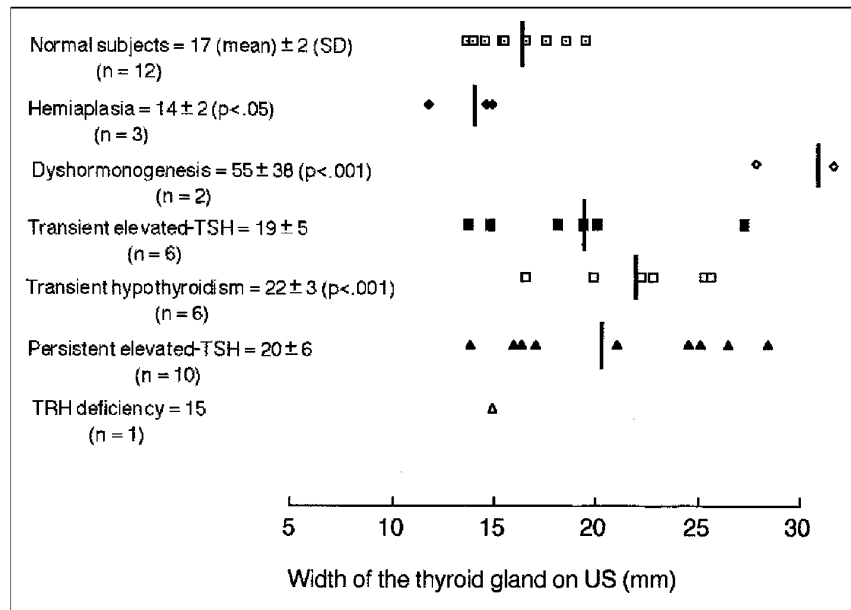
A, Longitudinal ultrasound scan demonstrates a hypoechoic mass (arrows) in the base of the tongue.

B, Left lateral image of iodine-123 scintigraphy depicts an ectopic thyroid tissue in the corresponding area.

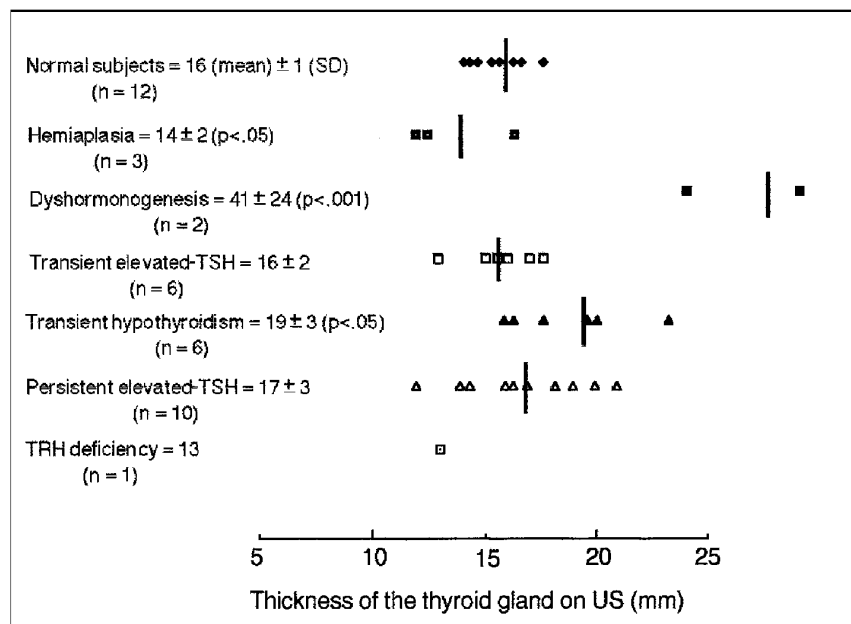
Fig 3. A, Mean width and statistical values.

B, Mean thickness and statistical values.

TRH indicates thyrotropin-releasing hormone; US, ultrasound.



A



B

When compared with the healthy controls, a significant increase in width or thickness was documented in dyshormonogenesis and transient hypothyroidism and a significant decrease in hemiaplasia.

Undetectable thyroglobulin in the serum was seen in the patient with thyroid aplasia. Thyroid tissue was not detected with ultrasound or scintigraphy.

Hemiaplasia of the thyroid gland was equally well diagnosed with scintigraphy as with ultra-

sound in three patients. Heterogeneous thyroid parenchyma was seen in one of the three patients, but the echogenicity was normal (Table 3).

Large thyroid glands (width or thickness > mean + 2 SD in normal subjects) were depicted with ultrasound in both patients with dyshormonogenesis (Fig 4). Heterogeneous parenchyma was seen in one patient, but the echogenicity was normal. Although these patients had an increased radioactive iodine uptake

TABLE 3: Echotextures and echogenicity of the thyroid gland in the normal place

Clinical Diagnosis	Echotextures		Echogenicity	
	Homogeneous	Heterogeneous	Normal	Low
Hemiaplasia (n = 3)	3	0	3	0
Dyshormonogenesis (n = 2)	1	1	2	0
Transient elevated thyrotropin (n = 6)	6	0	6	0
Persistent elevated thyrotropin (n = 10)	5	5	6	4
Transient hypothyroidism (n = 6)	5	1	6	0
Thyrotropin-releasing hormone deficiency (n = 1)	0	1	0	1

(42% and 46%) and positive discharge findings, these findings were not specific to this disorder. However, the diagnosis of dyshormonogenesis was established in the two patients when family history was added to the scintigraphic findings.

Large glands were seen in one of six patients with transient elevated thyrotropine, normal-size glands in four, and small glands (width or thickness < mean - 2 SD in healthy subjects) in one. Thyroid echotextures and echogenicity were normal in all these patients.

Of the six patients with transient hypothyroidism, an increase in radioactive iodine uptake was seen in two patients and a positive washout test result in two of three patients tested. A family history and follow-up laboratory studies established the diagnosis. Gland size was enlarged in four patients and normal in two. One patient showed heterogeneous echoes, but all patients had normal echogenicity.

All of the 10 patients with persistent elevated thyrotropin had normal radioactive iodine uptake values, and none had a positive washout test result. Thyroid size was large in 5 patients, normal in 4, and small in 2. Heterogeneous thyroid parenchyma was depicted in 5 patients and a decreased echogenicity in 4 (Fig 5).

A diagnosis of hypothalamic hypothyroidism was established in one patient with normal thyrotropin and low thyroxine levels combined with the other hormonal studies such as the normal pattern of thyrotropin response to exogenous thyrotropin-releasing hormone or other pituitary function tests (9). This patient showed a radioactive iodine uptake of 7.7% and a heterogeneous and hypoechoic thyroid gland of small size.

Discussion

Congenital hypothyroidism is a disease in which screening is beneficial, because mental

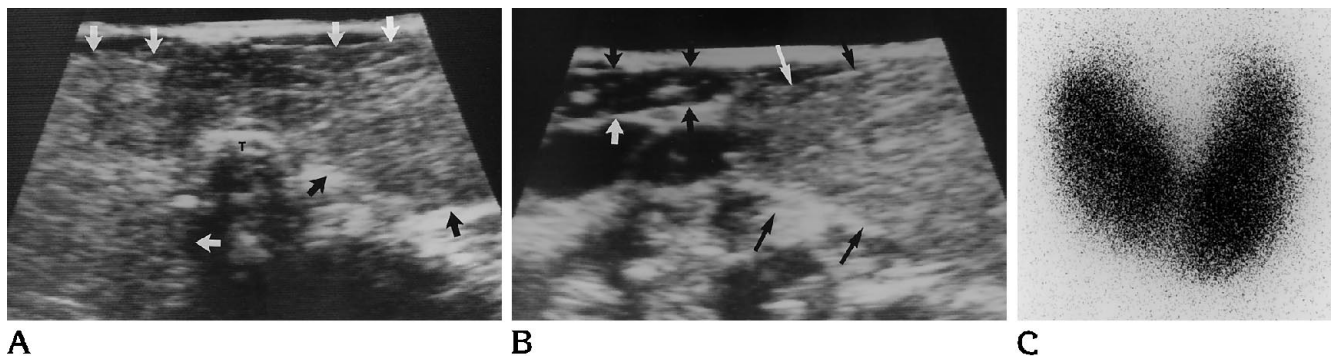


Fig 4. Case of dyshormonogenesis.

A, Transverse ultrasound scan demonstrates an enlarged, nonhomogeneous thyroid gland (arrows). Width was 82 mm, and thickness was 58 mm. T indicates trachea.

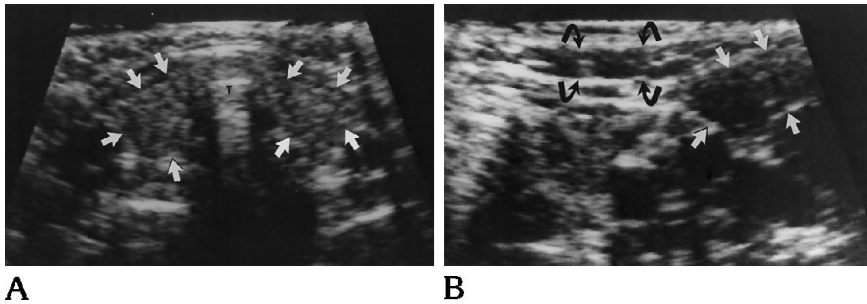
B, On the transverse ultrasound scan, the right lobe (thin arrows) of the thyroid gland appears more echogenic than the adjacent sternocleidomastoid muscle (thick arrows).

C, Anterior image of iodine-123 scintigraphy depicts an enlarged thyroid gland with intense uptake. The perchlorate washout test result was positive.

Fig 5. Case of persistent elevated thyrotropin.

A, An enlarged, nonhomogeneous thyroid gland (*arrows*) is depicted on a transverse ultrasound scan. Width was 21 mm, and thickness was 20 mm. *T* indicates trachea.

B, On the transverse ultrasound scan, echogenicity of the right lobe of the thyroid gland (*straight arrows*) is equal to that of the adjacent sternocleidomastoid muscle (*curved arrows*).



retardation is prevented in 85% of the patients with early initiation of therapy before the age of 3 months (1). Determining the cause of this condition is clinically important, because there are considerable differences in inheritance, prognosis, and therapy (1-4). Congenital hypothyroidism is caused by thyroid dysgenesis (aplasia, ectopia, or hypoplasia, 80%), dyshormonogenesis (10% to 15%), pituitary or hypothalamic hypothyroidism (less than 5%), transient hypothyroidism, and autoimmune mechanisms (1, 3). Thyroid replacement therapy should be instituted for all of the cases of biochemical confirmation of the diagnosis of hypothyroidism (1). Also, cases of ectopic gland should be treated even if laboratory data reveal borderline or compensated hypothyroidism to prevent complications from enlargement of lingual or sublingual thyroid tissues (3). Dyshormonogenesis attributable to enzymatic defects occurs in an autosomal recessive pattern of inheritance, and therefore, genetic counseling is required for patients with this disorder (2-4). Determining the presence or absence of functioning thyroid tissues is clinically important, because patients with functioning thyroid tissues have better neuropsychologic prognoses than those with none (3, 4).

Muir et al (4) reported in their comparative study of ultrasound and radionuclide study in 50 cases of congenital hypothyroidism that none of 13 ectopic thyroid tissues was detected with ultrasound and 4 cases of aplasia had a normal gland on ultrasound, and they concluded that ultrasound could not be the alternative to thyroid scintigraphy to define the cause of congenital hypothyroidism. However, their study was performed with a static B scanner equipped with a 5- or 7-MHz transducer. In our series, ultrasound showed 75% detection sensitivity for thyroid ectopia. Two (one in the mouth floor and one in the hypopharynx) of the eight ectopic glands were missed with ultrasound. Detection

failure in the former was caused by the similar echogenicity of the ectopic gland to the surrounding tissues and that in the latter by hindrance of the air in the laryngeal structure. We think that a physiologic isotope study is necessary for patients with absent glands in the normal location on ultrasound studies to confirm thyroid ectopias and to differentiate between ectopia and true aplasia.

Size, echotextures, and echogenicity of the thyroid gland considerably overlapped in each individual with a different cause. Nonetheless, a likely diagnosis may be suggested in limited cases by ultrasound findings alone; a markedly enlarged gland in the normal place may be a sign of dyshormonogenesis, goiter of hypoechogenicity of persistent elevated thyrotropin, a small hypoechoic thyroid gland of thyrotropin-releasing hormone deficiency, and a homogeneous gland of normal echogenicity of transient hypothyroidism or transient or persistent elevated thyrotropin. However, a specific etiologic diagnosis for the patients had to depend on the adding of the clinical data.

In this series, the etiologic diagnosis was made in all of the 20 patients with a thyroid gland in the normal anatomic location with hemiapsia, small size, or normal size equally well with ultrasound findings and chemical laboratory data as with scintigraphic findings and chemical laboratory data. However, radioactive iodine uptake measurement was useful to differentiate an etiologic diagnosis for patients with an enlarged thyroid gland in the normal anatomic place. Scintigraphically, an enlarged gland in the normal location with increased uptake and a positive perchlorate discharge test is diagnostic for an organification defect (most common in dyshormonogenesis) if Hashimoto thyroiditis is excluded (3, 10). Although these scintigraphic findings were not specific to this disorder, a correct diagnosis was obtained in the two patients with dyshormonogenesis when a

family history was added to the radioactive iodine uptake test results. Therefore, we think that of the patients who have the thyroid gland in the normal place, radioactive iodine and scintigraphy is still helpful for the patients with an enlarged gland that is diagnosed with ultrasound. In the remaining patients, ultrasound findings and laboratory data are sufficient for predicting a specific cause of possible congenital hypothyroidism.

Patients with hemiaplasia will have good prognoses, because hypothyroidism is documented only in 1 of 90 patients with this condition in the literature (11).

We classified the patients who had a thyroid gland in the normal location into two groups: prolonged (whose thyroid replacement therapy or careful follow-up was required for more than 1 year) and short (whose thyroid replacement therapy or careful follow-up was required for less than 1 year) clinical course. The former group included patients with dysmorphogenesis, persistent elevated thyrotropin, and thyrotropin-releasing hormone deficiency, and the latter group included patients with hemiaplasia, transient elevated thyrotropin, and transient hypothyroidism. In our series, the incidence (7 of 13) of heterogeneous thyroid parenchyma in the group of prolonged clinical course was significantly ($P < .05$) higher than that (1 of 15) in the group of short clinical course. Similarly, the incidence (5 of 13) of hypoechoic gland in the group of prolonged clinical course was significantly ($P < .05$) higher than that (0 of 15) in the group of short clinical course.

We suggest that careful ultrasonographic analysis of the neck in patients with suspected congenital hypothyroidism in association with chemical laboratory data is sufficient in more than half (54%) of such patients. Scintigraphy is required only in patients with no visibility of the

thyroid gland in the normal location and patients with an enlarged gland in the normal anatomic place with ultrasound. Sonographic analysis has a potential to predict the prognosis of patients with suspected congenital hypothyroidism. However, more experience is necessary before a final conclusion regarding the role of ultrasound in this condition can be made.

Acknowledgments

We thank Masanori Nishikawa, MD, for providing clinical data and Reina and Anna Takashima for encouragement.

References

1. Dussault JH, Fisher DA. Hypothyroidism in infants and children. In: Braverman LE, Utiger RD, eds. *The Thyroid*. 6th ed. Philadelphia: JB Lippincott, 1991:1219-1236
2. Heyman S, Crigler JF, Treves S. Congenital hypothyroidism: ¹²³I thyroidal uptake and scintigraphy. *J Pediatr* 1982;101:571-574
3. Wells RG, Duck SC. Technetium 99m pertechnetate thyroid scintigraphy: congenital hypothyroid screening. *Pediatr Radiol* 1986; 16:368-373
4. Muir A, Daneman D, Daneman A, Ehrlich R. Thyroid scanning, ultrasound, and serum thyroglobulin in determining the origin of congenital hypothyroidism. *Am J Dis Child* 1988;142:214-216
5. Pöyhönen L, Lenko HL. Ultrasound in congenital hypothyreosis. *Acta Paediatr Scand* 1984;73:523-526
6. Ueda D, Mitamura R, Suzuki N, Yano K, Okuno A. Sonographic imaging of the thyroid gland in congenital hypothyroidism. *Pediatr Radiol* 1992;22:102-105
7. Miyai K, Amino N, Nishi N, et al. Transient infantile hyperthyrotropinaemia: report of a case. *Arch Dis Child* 1979;54:965-967
8. Miki K, Nose O, Miyai K, Yabuuchi H, Harada T. Transient infantile hyperthyrotropinaemia. *Arch Dis Child* 1989;64:1177-1182
9. Pinchera A, Martino E, Faglia G. Central hypothyroidism. In: Braverman LE, Utiger RD, eds. *The Thyroid*. 6th ed. Philadelphia: JB Lippincott, 1991:968-984
10. Stanbury JB. Inherited metabolic disorders of the thyroid system. In: Braverman LE, Utiger RD, eds. *The Thyroid*. 6th ed. Philadelphia: JB Lippincott, 1991:934-941
11. Melnick JC, Stemkowski PE. Thyroid hemiagenesis (hockey stick sign): a review of the world literature and a report of four cases. *J Clin Endocrinol Metab* 1981;52:247-251